



Clinical case

Aesthetic Management of the Anterior Sector with Minimally Invasive Ceramic Restorations.

Luis Leonel Gutiérrez-Huizar¹, Carlos Antonio Villalvazo-Velasco²,
Jacqueline Adelina Rodríguez-Chávez³, Karina Magaña-Curiel³,
Ricardo Curiel-González³, Juan Delgado-Sánchez³

- ¹. Alumno de la Especialidad en Prostodoncia. Departamento de Clínicas Odontológicas Integrales. Centro Universitario de Ciencias de la Salud. Universidad de Guadalajara.
- ². Egresado de la Especialidad en Prostodoncia. Departamento de Clínicas Odontológicas Integrales. Centro Universitario de Ciencias de la Salud. Universidad de Guadalajara.
- ³. Profesor de la Especialidad en Prostodoncia. Departamento de Clínicas Odontológicas Integrales. Centro Universitario de Ciencias de la Salud. Universidad de Guadalajara.

Corresponding author:

Jacqueline Adelina Rodríguez-Chávez.

E-mail: jacqueline.rchavez@academicos.udg.mx

Received: March 2021

Accepted: June 2021

Cite as:

Gutiérrez-Huizar LL, Villalvazo-Velasco CA, Rodríguez-Chávez JA, Magaña-Curiel K, Curiel-González R, Delgado-Sánchez J. Aesthetic Management of the Anterior Sector with Minimally Invasive Ceramic Restorations. Rev Odont Mex. 2022; 26(3): 28-35. DOI: 10.22201/fo.1870199xp.2022.26.3.87626

ABSTRACT

Introduction: Dyschromia, morphological alterations, and interdental spaces are some of the factors that compromise the aesthetics of the smile. Patients go to the dental clinic to solve these types of problems and obtain the desired smile. **Objective:** To present a minimally invasive work protocol of the anterior sector with dental veneers. **Case presentation:** A 22-year-old female patient. Her reason for consultation: "I want resins in my teeth". Dental fluorosis grade TF5, diastema at the level of teeth 11 and 21, dental disproportion and altered passive eruption in the maxillary

premolar area were diagnosed. Prosthodontic and surgical procedure was chosen. The treatment plan was structured in two phases. In the first, pre-prosthetic phase, crown lengthening was carried out at the level of the maxillary first and second premolars. The second, prosthetic phase, consisted of dental reduction for the restoration, preparation and cementation of 10 bonded restorations of LT lithium disilicate in BL1 shade, in the anterior sector. After treatment, an improvement in the shape and colour of the anterior sector was achieved, as well as an immediate disocclusion provided by the new canine guidance and anterior guide. **Conclusions:** The bonded ceramic restorations and periodontal surgery allowed us to meet the stated objectives, with a gentle execution of the treatment but achieving an aesthetic and functional smile.

Keywords: Bonded ceramic restorations, veneers, minimally invasive, lithium disilicate, aesthetics.

INTRODUCTION

In today's society, beauty standards that include a white and harmonious smile are synonymous with a person enjoying good health and oral safety; this is why patients often go to the dental clinic to get that long-awaited smile. There are different treatments that, individually or together, can lead us to meet the expectations of patients to achieve both a functional and aesthetic smile. As dentists we must know the indications and limitations of each treatment. When diagnosing dental dyschromia, we can think about the use of whitening agents to treat them, but this is not always achieved, as is the case with intrinsic dyschromia, which occur from the development of the tooth¹. An example of these are teeth with fluorosis, which are usually characterised by having white lines or in more severe cases, cloudy areas that can be discrete or confluent^{2,3}. Another problem that patients often report is interdental spaces, known as diastemas. In this type of problem, the first treatment option is orthodontic, but sometimes it is not possible to completely close these spaces. At this point we can think about combining orthodontics with some prosthetic treatment^{4,5}. When a patient presents a combination of these aesthetic problems, it is a challenge to be able to provide a solution for both. A treatment that can successfully and conservatively resolve this type of dyschromia is porcelain dental veneers^{5,6}.

The purpose of this article is to present a clinical case of a 22-year-old patient in whom the aesthetics of the anterior sector was improved by means of dental veneers, which followed a work protocol so that the treatment performed was minimally invasive.

PRESENTATION OF THE CLINICAL CASE

A 22-year-old female patient, who came with the following reason for consultation: *"I want resins in my teeth"*. She said that 3 years ago she completed orthodontic treatment and orthognathic surgery. As a sequel to the surgical treatment, the patient presented bilateral mandibular paraesthesia. She came without using a dental retainer after orthodontic treatment. She had a mesocephalic facial biotype with a straight profile, an interpupillary line not parallel to the commissural line or the incisal line. The facial midline did not coincide with the dental midline as the latter was deviated to the right side by 2 mm. Her lips were behind the

E-line, and she had medium lip dynamics. Altered passive eruption was diagnosed at the level of maxillary premolars. Her nasolabial angle was 100° , also, facial asymmetry was observed at the lower right edge of the mandible (Figure 1. A). In the dental analysis of the anterior sector, it showed brown and white pigmentations attributed to dental fluorosis grade TF5², gingival disharmony, diastema at the level of teeth 11 and 21, and unfavourable dental morphology (Figure 1. B). The occlusal analysis models showed, on the one hand, that on the right side it was not possible to establish a Class molar due to the absence of tooth 46, and Class I canine; and on the left side, Class I molar and Class I canine were present, with overjet and overbite of 4 mm (Figure 1. C). For this reason, the treatment objectives were to achieve a symmetrical gingival architecture, change the shape and colour of the teeth in the anterior sector of the maxilla, and close the diastema between teeth 11 and 21.

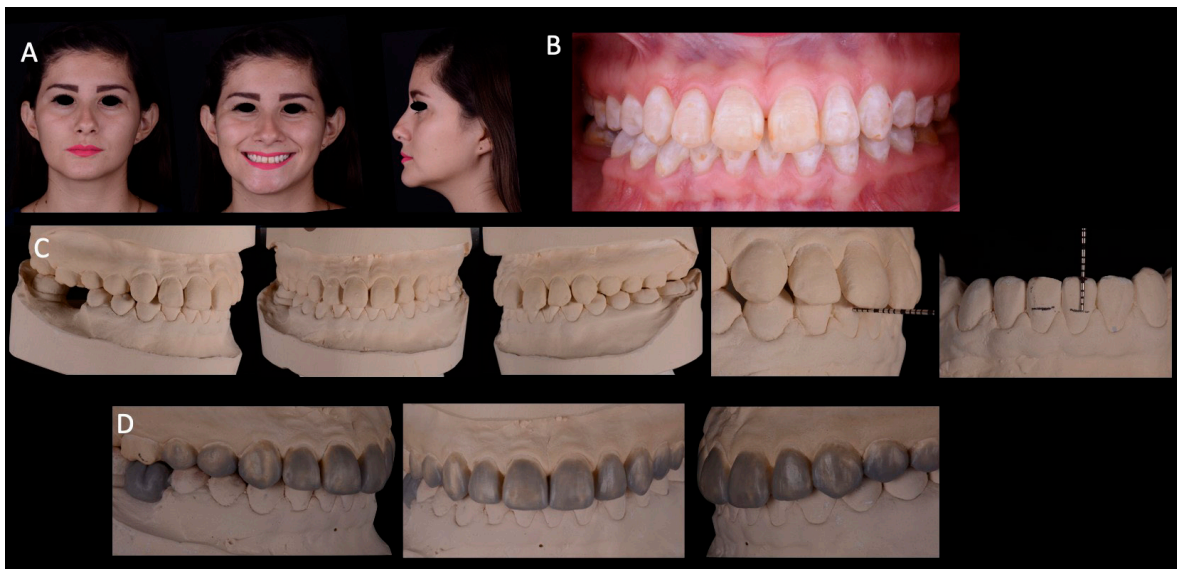


Figure 1. Extraoral and Intraoral photographs, study models and diagnostic wax-up. A) Initial photographs of the front and side at rest, and the front smiling. B) Initial Intraoral photography of the front. C) Study models, right lateral in occlusion, frontal in occlusion, left lateral in occlusion, overjet and overbite. D) Photographs of the diagnostic wax-up, right side, frontal in occlusion, left side.

The treatment was divided into two phases: 1, pre-prosthetic phase, where crown lengthening was performed at the level of the first and second maxillary premolars. 2, prosthetic phase; consisting of dental reduction for the restoration, preparation and cementation of 10 bonded restorations of LT lithium disilicate in BL1 shade, in the anterior sector.

Interdisciplinary treatment began with the periodontics area where crown lengthening of teeth 15, 14, 24 and 25 was performed, since they presented altered passive eruption and high labial or gingival dynamics, according to Fradeani⁷. Ten days after surgery, the sutures were removed and a post-surgical review was performed; 12 weeks were allowed for the periodontal tissue to heal⁸. Preliminary two-step impressions were taken with silicone by addition (Virtual Refill Putty Regular, Ivoclar Vivadent AG, Liechtenstein) heavy putty and light consistency. With the models obtained, a diagnostic wax-up of teeth 15 to 25 was carried out (Figure 1. D), on which preparation guides (Figure 2. A) and a silicone key (Zetalabor, Zhermack SpA, Italy)

were manufactured to create a mock-up with bis-acrylic resin (3M™ Protemp™ 4, 3M espe Deutschland GmbH, Germany) in A1 shade (Figure 2B).

Reduction grooves were prepared on the mock-up to a depth of 0.3 mm with a BR-45 bur (Mani® dia-burs®, Mani Inc., Japan), the mock-up was removed, and the guide grooves were recorded on the teeth, which were marked with a graphite. Continuing with the preparation, a TR-13 bur (Mani® dia-burs®, Mani Inc., Japan) was used to perform the wear at the indicated depth (0.3 to 0.6 mm), which was confirmed with the reduction guides. The surface finish preparation was carried out using TR-13F, TR-13EF burs (Mani® dia-burs®, Mani Inc., Japan), Sof-Lex discs and polishing rubber (3M™ Sof-Lex™ Finishing Strips Basic Kit, 3M espe Deutschland GmbH, Germany), the finish was at the level of the equigingival margin. Once the preparation was completed, the double thread gingival retraction technique was used⁹, the first thread being #000 black and a second thread being #0 purple (Ultrapak™ and Ultrapak™ E, Ultradent Products Inc., South Jordan, Utah, USA), to select the opacity of the glass-ceramic (Figure 2. C) we used the Shade Navigation App (IPS e.max Shade Navigation App, Ivoclar Vivadent AG, Liechtenstein).

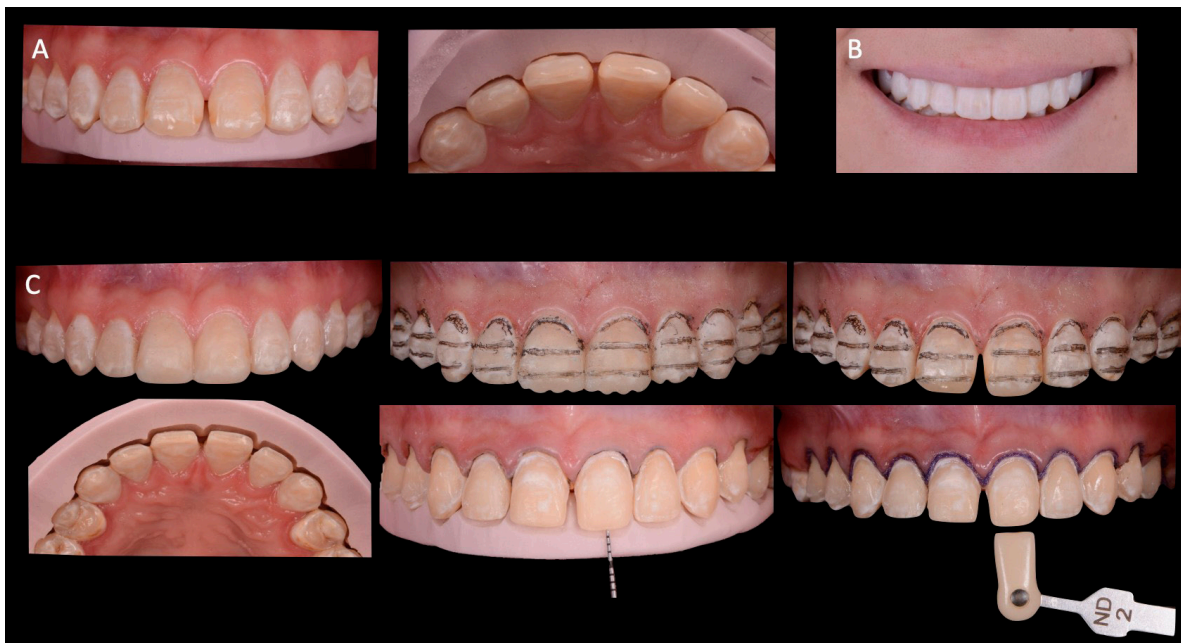

Figure 2. Reduction guide, mock-up, dental reduction process and shade taking. A) Vestibular view of the reduction guide in the mouth and incisal view of the reduction guide at the middle third level. B) Frontal smile with a mock-up. C) Intraoral photographs of the dental reduction process and the shade taking of the mock-up made from second premolar to second premolar, preparation guide grooves carved on the mock-up and marked with graphite, guide grooves marked on the teeth once the mock-up has been removed, corroboration of the dental reduction with the reduction guide from an incisal view at the level of the incisal third, dental reduction of 1 mm from a vestibular view corroborated with a probe and reduction guide, and stump shade measurement with colorimeter. The Shade Navigation App was used to select the opacity of the glass-ceramic.

The impression was taken in one step with heavy consistency Vinyl Polysiloxane (3M™ Imprint^{MT} II Garant^{MT} Quick Step Heavy Body, 3M espe Deutschland GmbH, Germany) and light consistency silicone (3M™ Imprint^{MT} II Garant^{MT} Light Body, 3M ESPE Deutschland GmbH,

Germany). Additionally, with the waxing, guides were made to provisionalize the teeth with bis-acrylic resin in A1 shade. The final restorations were performed with pressed LT lithium disilicate tablets in BL1 shade (IPS e.max Press LT, Ivoclar Vivadent AG, Liechtenstein). The ink GLUE technique created and described by Ivan Ronald Huasca was used in the texturing of the veneers. For the cementation of the restorations, absolute isolation was performed of teeth 16 to 26 with a thick rubber dam (Dique Nictone, MDC® Dental, México) (Figure 3. A); veneers were conditioned by placing 5% hydrofluoric acid (IPS Ceramic Etching Gel, Ivoclar Vivadent AG, Liechtenstein) for 20 s (Figure 3. B), the acid was washed from the surface with a jet of water and air, then 35% phosphoric acid (Ultra-Etch™, Ultradent Products Inc., South Jordan, Utah, USA) was placed to remove the hexafluorosilicate residues (Figure 3. C). A wash was carried out with water and air to remove the phosphoric acid, then the silane (Porcelain Primer/Bis-Silane™, Bisco, Inc., Schaumburg, Illinois, USA) was placed for 60 s (Figure 3. D). The tooth surface was conditioned with the same protocol on all teeth, starting with surface sandblasting with aluminium oxide (Figure 3. E), followed by enamel etching for 15 s with 35% phosphoric acid (Figure 3. F).

It was washed with plenty of water and air for 20 s, polymerized dental adhesive (All Bond Universal®, Bisco, Inc., Schaumburg, Illinois, USA) was applied and rubbed for 15 s, applying air with the triple syringe and volatilized to subsequently cement the crowns with translucent light-curing resinous cement (eCement L/C®, Bisco, Inc., Schaumburg, Illinois, USA) and finally it was photopolymerized with a curing light lamp (1200 mW, 3M™ Elipar™ DeepCure, 3M espe Deutschland GmbH, Germany) for 20 s. The order of cementation that was carried out included first the restorations of teeth 11 and 21 and then proceeded to cement from the posterior part towards the midline (Figure 3. G).

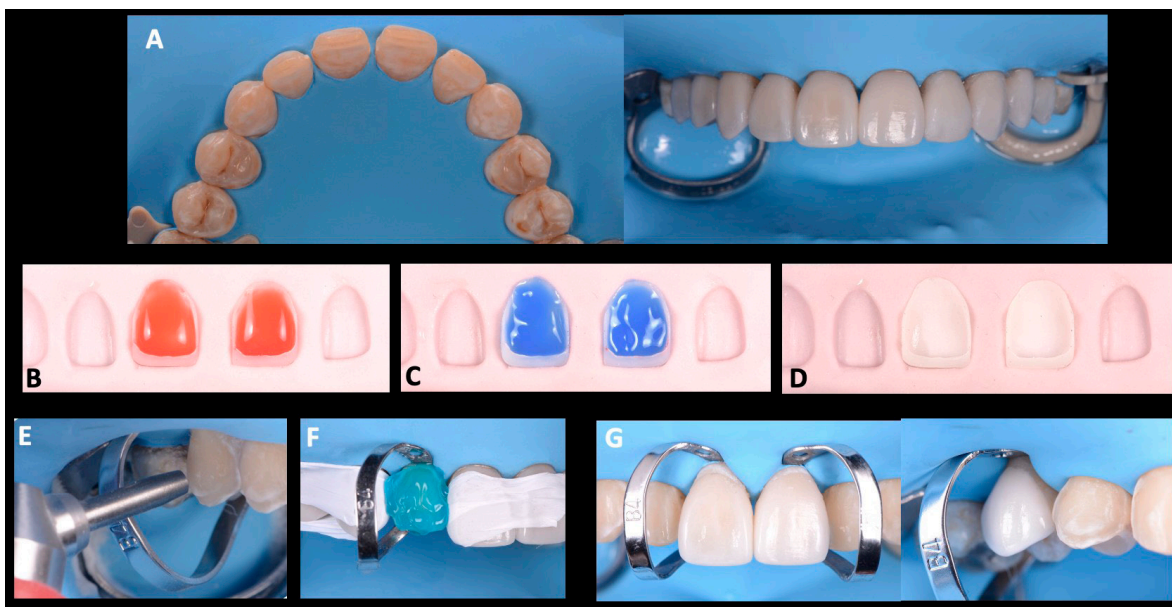


Figure 3. Intraoral photographs of the conditioning process of the veneers, the tooth surface and the cementing of the restorations. A) Absolute isolation from an occlusal view and testing of veneers from a vestibular view. B) Conditioning of veneers with 5% hydrofluoric acid. C) Removal of hexafluorosilicate residues with 35% phosphoric acid. D) Silane placement. E) Surface sandblasting with aluminium oxide. F) Etching the enamel with 35% phosphoric acid for 15 seconds. G) Cementation of the veneers of teeth 11 and 21, and cementation of the posterior part towards the midline.

When the stated objectives were met, the dental aesthetics of the anterior sector improved; when smiling the gingival architecture was more harmonious; the dyschromia caused by fluorosis was covered; a better shape and proportion in size was given to the teeth; the existing diastema was closed; the smile line was aligned following the curvature of the lower lip; it was possible to match the facial midline with the dental midline, and the establishment of organic occlusion characteristics was obtained (Figure 4. A-B).

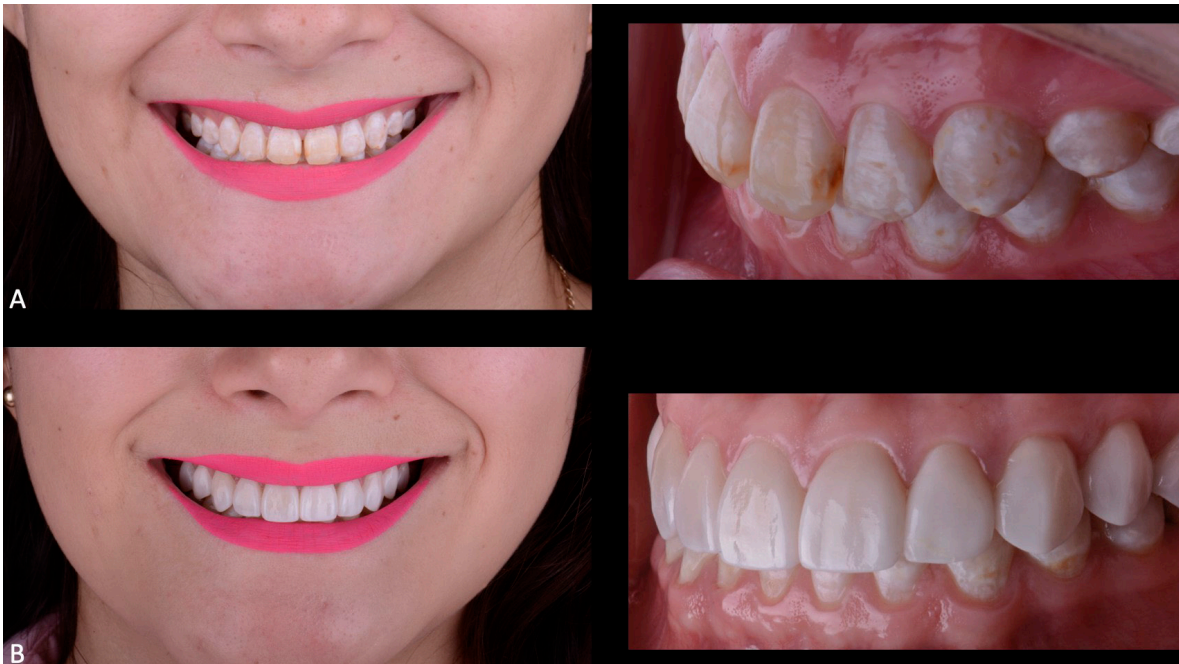

Figure 4. Initial and final facial and intraoral photographs. A) Front smiling and lateral $\frac{3}{4}$ initial intraoral. B) After cementation of the veneers from the smiling front and lateral $\frac{3}{4}$ intraoral.

DISCUSSION

In the present case, the patient comes for consultation because she was not satisfied with her smile. Among the criteria used for the choice of indirect treatment for the aesthetic management of the anterior sector, the indications by Belser *et al.*, were taken into account. These include masking dental dyschromia and changes in the morphology of the anterior teeth⁵.

The high posterior smile and altered passive eruption that the patient presented were treated in the first phase of treatment. This condition is described by Silva *et al.*, as the situation where the gingival margins are incisally attached to the cervical convexity of the tooth, resulting in short and square clinical crowns that are not perceived as aesthetic¹⁰. The healing time allowed after the surgical intervention was recommended by Lack, who points out that after 3 months the preparations and final impressions can be made, since the periodontal tissue can be stable at that time⁸.

Diastemas are aesthetic problems with a high prevalence in adults between 1.6% and 25.4%, and are defined as a space greater than 0.5 mm between the proximal surfaces of the two central incisors^{11,12}. As Gupta mentions, orthodontic treatment is often not enough to correct spaces and restorative work is necessary to optimise these results¹¹; due to the advantages

that indirect restorations have compared to direct restorations, such as greater longevity, more natural appearance due to the shape, colour and brightness of these restorations. Dental veneers are often used to resolve this malocclusion^{5,11-13}. Fluorosis, like diastemas, usually causes patients to feel dissatisfied with their smile due to white lines or, in more severe cases, cloudy areas present on the teeth³, thus requiring aesthetic treatment to correct. Treatment options include teeth whitening and micro-abrasions. These treatments are not usually efficient when medium-severity fluorosis is present, which is why in many cases a treatment with bonded ceramic restorations is chosen^{5,14,15}. As we see with these restorations, we can solve several of the problems that affect the harmony of the patient's smile. By following this path, we are able to be as non-invasive as possible, obtaining aesthetic and functional results^{5,9}.

To obtain the desired results and avoid being invasive, a dental reduction protocol is suggested based on the final volume of the restoration, aided by reduction guides, as well as preparation grooves that are carved on the patient's mock up. These indicate the reduction necessary for the preparation of the restorations, preserving most of the dental structure intact, this reduction protocol is described by Magne & Belser in 2004¹⁶. Buzetto *et al*¹³. report a work protocol similar to the one we used, obtaining both aesthetic and functional results for the patient.

CONCLUSION

With a correct diagnosis and the development of the appropriate protocols for the proposed treatment plan, favourable and satisfactory results for the patient can be guaranteed. The use of bonded ceramic restorations allows us to resolve cases where aesthetics and function are compromised, being a conservative treatment in the wear of the dental structure with a favourable long-term prognosis.

BIBLIOGRAPHIC REFERENCES

1. Joiner A. The bleaching of teeth: a review of the literature. *J Dent.* 2006; 34(7): 412-419. DOI: 10.1016/j.jdent.2006.02.002
2. Thylstrup A, Fejerskov O. Clinical appearance of dental fluorosis in permanent teeth in relation to histologic changes. *Community Dent Oral Epidemiol.* 1978; 6(6): 315-328. DOI: 10.1111/j.1600-0528.1978.tb01173.x
3. Al-Sugair MH, Akpata ES. Effect of fluorosis on etching of human enamel. *J Oral Rehabil.* 1999; 26(6): 521-528. DOI: 10.1046/j.1365-2842.1999.00391.x
4. Spear FM. The esthetic correction of anterior dental mal-alignment conventional vs. instant (restorative) orthodontics. *J Calif Dent Assoc.* 2004; 32(2): 133-141. DOI: 10.1080/19424396.2004.12223953
5. Belser UC, Magne P, Magne M. Ceramic laminate veneers: continuous evolution of indications. *J Esthet Restor Dent.* 1997; 9(4): 197-207. DOI: 10.1111/j.1708-8240.1997.tb00941.x
6. Gurel G, Sesma N, Calamita MA, Coachman C, Morimoto S. Influence of enamel preservation on failure rates of porcelain laminate veneers. *Int J Periodontics Restorative Dent.* 2013; 33(1): 31-39. DOI: 10.11607/prd.1488
7. Fradeani M. *Rehabilitación estética en prostodoncia fija. Volumen 1, análisis estético.* Barcelona: Quintessence, 2006.

8. Lack JD. Aesthetic crown lengthening: A step by step surgical guide and biologic considerations. *Alpha Omegan*. 2009; 102(4): 133-141. DOI: 10.1016/j.aodf.2009.11.001
9. Spear F. Using margin placement to achieve the best anterior restorative esthetics. *J Am Dent Assoc*. 2009; 140(7): 920-926. DOI: 10.14219/jada.archive.2009.0287
10. Silva CO, Soumaille JMS, Marson FC, Progiante PS, Tatakis DN. Aesthetic crown lengthening: periodontal and patient-centred outcomes. *J Clin Periodontol*. 2015; 42(12): 1126-1134. DOI: 10.1111/jcpe.12482
11. Gupta, SP. Maxillary Midline Diastema: A Contemporary Review. *EMS Dent J*. 2018; 1(1): 1-12. <https://www.researchgate.net/profile/Sanjay-Gupta-25/publication/326827106>
12. Maluly-Proni AT, Oliveira-Reis B, Assunção WG, Dos Santos PH. Minimum intervention management of diastema closure using cordless displacement system and laminate veneers: A 2-year follow-up. *Eur J Dent*. 2018; 12(3): 446-449. DOI: 10.4103/ejd.ejd_208_18
13. Buzetto SC, Pedreira PR, Damasceno JE, Pierote JJA, Marchi GM, Paulillo LA. Minimally invasive approach to diastema closure using lithium disilicate porcelain veneers: clinical report. *Braz Dent Sci*. 2018; 21(4): 491-497. DOI: 10.14295/bds.2018.v21i4.1633
14. Riahi Z, Moussa AB, Jbeniany M, Harzallah B, Cherif M, Hadyaoui D. Prosthetic management of dental fluorosis. *Acta sci dental sci*. 2019; 3(5): 19-23. <https://actascientific.com/ASDS/pdf/ASDS-03-0511.pdf>
15. El Mourad AM. Aesthetic rehabilitation of a severe dental fluorosis case with ceramic veneers: A step-by-step guide. *Case Rep Dent*. 2018; 2018: 4063165. DOI: 10.1155/2018/4063165
16. Magne P, Belser UC. Novel porcelain laminate preparation approach driven by a diagnostic mock-up. *J Esthet Restor Dent*. 2004; 16(1): 7-16. DOI: 10.1111/j.1708-8240.2004.tb00444.x