



Clinical case

Transalveolar Maxillary Sinus Elevation Through Conservative Technique and Simultaneous Placement of Dental Implant: Case Report

Kenny Camargo Coronell¹, Jaime Javier Guzmán de Ávila²,
Antonio Díaz Caballero³, Mauro Marincola⁴

- ¹. Facultad de Odontología, Universidad de Cartagena. Semillerista grupo de investigación GITOUC, Cartagena de Indias, Colombia. Correo: kcamargoc@unicartagena.edu.co. ORCID: <https://orcid.org/0000-0002-8883-7010>
- ². Facultad de Odontología, Universidad de Cartagena. Grupo de investigaciones en Salud Pública GISPOUC, Cartagena de Indias, Colombia. Correo: jguzmand@unicartagena.edu.co. ORCID: <https://orcid.org/0000-0002-0529-5915>
- ³. Facultad de Odontología, Universidad de Cartagena. Grupo de investigación GITOUC, Cartagena de Indias, Colombia. Correo: adiazc1@unicartagena.edu.co. ORCID: <https://orcid.org/0000-0001-9693-2969>
- ⁴. Unidad de implantes dentales, Facultad de Odontología, Universidad de Cartagena. Correo: mmarincola@gmail.com. ORCID: <http://orcid.org/0000-0002-9308-4279>

Corresponding author:

Kenny Camargo Coronell
Universidad de Cartagena, Facultad de Odontología,
Departamento de Investigaciones. Campus de la Salud,
Barrio Zaragocilla, Cartagena (Colombia).
E-mail: kcamargoc@unicartagena.edu.co

Received: june 2021

Accepted: august 2021

Cite:

Camargo Coronell K, Guzmán de Ávila JJ, Díaz Caballero A, Marincola M. Transalveolar Maxillary Sinus Elevation Through Conservative Technique and Simultaneous Placement of Dental Implant: Case Report. *Rev Odont Mex.* 2022; 26(2): 71-76. DOI: 10.22201/fo.1870199xp.2022.26.2.87327

Abstract

Introduction: Oral implantology has many challenges, one of which is rehabilitation in regions with low bone volume and height. Currently, short dental implants have been used, demonstrating good osseointegration with excellent ability to retain an abutment and manage forces. This size of implants turns out to be less invasive compared to the surgical technique used in the oral cavity. **Objective:** To demonstrate good adaptability in the placement of short dental implants in the posterior sector of the upper maxilla, using a conservative technique and appropriate instruments. **Case presentation:** a 52-year-old female patient with decreased height of the alveolar ridge in the premolar area, presents a type of ridge according to Seibert class-II, describing the transalveolar maxillary sinus elevation technique, using the STRAUSS & CO® Safe Sinus Lift Kit and the simultaneous placement of a dental implant with a primary retention grade. **Conclusion:** For this clinical case, the use of short dental implants in the atrophic posterior maxilla was of vital importance; with the conservative technique, the risk of morbimortality in the patient was reduced and was essential in terms of cost-benefit, in addition, these implants have the load-bearing capacity.

Keywords: Dental implants, rehabilitation, maxillary sinus (Decs, Bireme).

INTRODUCTION

The maxilla is a major challenge for dental implant treatment due to its anatomy, poor availability and quality of bone, due to the premature loss of its natural dentition. Progressive atrophy of the maxilla causes a process of alveolar bone remodelling that increases with the action of removable prostheses¹.

One of the main criteria for choosing a candidate patient to receive dental implants is the availability of bone volume. The literature states that the minimum bone dimensions required for dental implant placement should be 5 mm wide (bucco-palatal/lingual) and between 7 and 10 mm high. However, in practice there are a large number of patients who require dental implants that do not meet the ideal bone conditions. Among these, the most common is insufficient bone volume, which may be due to atrophy of the alveolar ridge to the absence of teeth, periodontal disease or as a consequence of some pathology or trauma².

The vertical, centrifugal and centripetal resorption of the jaws can often become an obstacle to rehabilitation with the ideal dental implant. Various techniques have been used to improve the anatomy of the site that will receive the dental implant: block grafts, guided bone regeneration, distraction osteogenesis and maxillary sinus elevation; however, these treatments are not free of limitations and complications³.

Currently, we can find a trend in research to evaluate the performance of dental implants with low height, called short dental implants (5 to <10 mm), which can be used as a procedure or a simpler alternative to solve anatomical and physiological limitations, demonstrating good osseointegration with excellent capacity to retain an abutment and manage forces. This size of dental implants is less invasive in terms of the surgical technique used in the oral cavity, from a biomechanical point of view. Dental implants that are inserted into the atrophic maxilla must be located in appropriate locations for their functional load^{4,5}.

The aim of this case is to demonstrate good osseointegration on the placement of short dental implants in the posterior sector of the upper maxilla using a conservative technique and appropriate instruments.

CLINICAL CASE PRESENTATION

A 52-year-old female patient, from the city of Cartagena de Indias, who came for consultation due to aesthetic and functional discomfort. She reports that she has had this problem for more than five years. It does not describe a significant personal medical history.

Evaluation with an intraoral examination showed clinical and radiographic absence of teeth 15 and 16, a decrease in bone height of the alveolar ridge in the area of the premolars, a type of ridge according to Seibert class-II, which is a limitation for the placement of dental implants with the conventional rehabilitation method (Figure 1A-B). The digital radiography showed the low bone height, revealing an average height of 4.90 mm from the alveolar ridge to the maxillary sinus floor for the placement of a dental implant (Figure 1B). An atraumatic surgery, such as transalveolar maxillary sinus elevation with immediate loading using a short dental implant, was suggested as a treatment plan. Paraclinical tests were ordered, which showed the patient's general condition in normal values, which allowed the surgery to be scheduled.

After asepsis and antisepsis of the surgical area to be intervened, an intrasulcular incision was made respecting the papillae of teeth 14 and 13, with distal crestal extension on the alveolar ridge, preparing a full thickness flap allowing vision of the surgical field and then the STRAUSS & CO® Safe Sinus Lift Kit was used (Figure 2), which allows conservative osteotomy with depth stop, thus controlling entry into anatomical repairs such as the floor of the maxillary sinus. The kit has different drills with atraumatic round active parts and the possibility of control by means of stable stops on the alveolar ridge when entering the hard tissue area, thus avoiding surgical accidents, such as perforation of the Schneiderian membrane. This type of conservative techniques through the use of the atraumatic kit allows the preparation of the surgical site, controlling the perforation of the workplace in a more precise and rapid manner (Figure 3A-B). A drill that controls the depth of entry to 5 mm was used; mechanical surgical drills were subsequently used at 50 RPM without irrigation for the preparation of the surgical site and transalveolar entry of beta tricalcium phosphate biomaterial, using manual osteotomes that

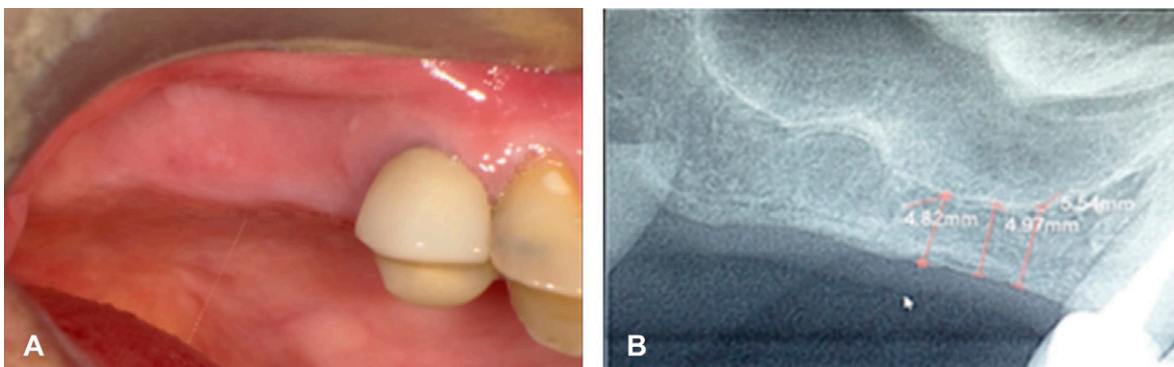


Figure 1. Initial photographs. A. Clinical photograph of healthy soft tissues. B. Digital radiography showing the low bone height with respect to the maxillary sinus floor.



Figure 2. STRAUSS & CO® Safe Sinus Lift Kit Instrumentation.

enabled the displacement of the maxillary sinus floor and Schneiderian membrane, favouring the increase in length in the new bone height obtained.

Once the surgical site was prepared and the ideal bone height had been increased, the short dental implant with dimensions of 4.5 x 6.0 mm was immediately placed, obtaining stability and primary fixation with the ideal mechanical drilling; following the dental implant

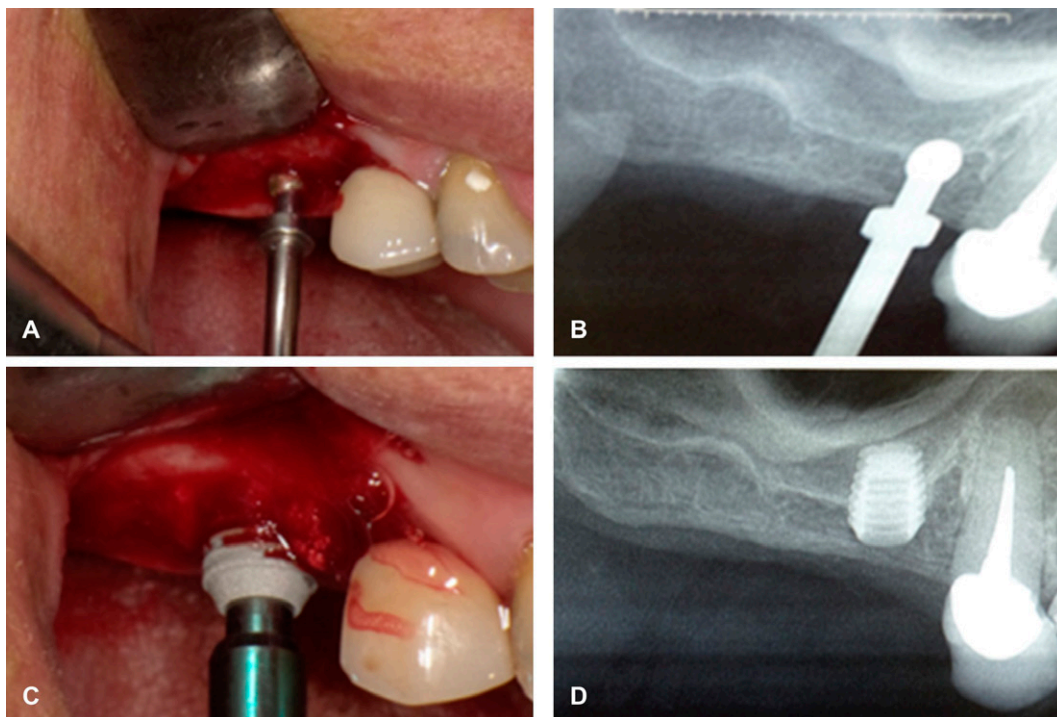


Figure 3. Surgical procedure. A. Surgical Site Preparation. B. Control digital Radiography of the preparation of the surgical site. C. Short dental implant placement. D. Final digital radiography with the short dental implant, without drilling the maxillary sinus.

manufacturer's protocol. Finally, the soft tissues were closed, with the continuous suture technique, without any surgical complications (Figure 3C).

Three months after dental implant placement, clinical controls and diagnostic radiographies were carried out, which confirmed excellent osseointegration, excellent retention capacity, no lesions in the surgical area around the implant, ideal adaptability, without perforation of the maxillary sinus floor or the Schneiderian membrane. In a second surgical phase, the dental implant was verified as stable, without mobility and tissues in good health, corroborating the high success rate of this minimally invasive conservative technique (Figure 3D).

DISCUSSION

The posterior sector of the maxilla has anatomical and morphological characteristics that complicate the placement of dental implants. The combination of poor bone volume and quality, together with a frequently hyperpneumatized maxillary sinus, makes the surgeon frequently resort to advanced techniques⁶.

For Sánchez *et al.*, maxillary sinus elevation is usually the first treatment option. Currently, a controlled drilling technique is implemented with a cylinder for bone in the maxillary ridge, this is done manually by pushing it into the maxillary sinus, to later fill the defect created. Its complications are: that the bone core can remain in the trephine drill, without the existence of stability for the bone inside the maxillary sinus and the height to be gained is limited by the remaining height of the ridge. Its advantages are: it allows elevation in areas compromised by the existence of adjacent teeth, it is fast and not very traumatic⁷.

On the other hand, Thoma *et al.* mention that the lateral window technique, autologous bone grafts for bone height gain and/or zygomatic implants are avoided. When comparing short dental implants with conventional dental implants with maxillary sinus elevation (immediate and delayed) in posterior maxillary sectors, it is concluded that statistically both types of dental implants have high and predictable survival rates. But taking into account that longer dental implants in the maxillary sinus present a greater number of biological complications, increased morbidity, costs and surgical time, short dental implants may represent the treatment alternative of choice⁸. The lateral window technique is strongly related to complications such as perforation of Schneiderian membrane and sinusitis⁹.

Anitua, in 2023, mentions that currently short dental implants are an alternative in the rehabilitation of the maxilla and mandible with extreme vertical resorption, with survival rates very similar to those of conventional dental implants, even reaching slightly higher figures (99.3%). The acquisition of sufficient primary stability is crucial to achieve proper osseointegration of the dental implant. For this, it is important to adapt the drilling, the characteristics of the surgical site, the use of conservative techniques with the bone and the possibility of placing larger diameter dental implants, which allow three-dimensional anchors in those areas with greater bone reinforcement (sinus cortical) and seek vestibular-palatal corticalization instead of apical corticalization¹⁰.

In the literature, we can find articles with success rates (good clinical, radiographic, aesthetic results) and survival (number of dental implants that are still installed at the end of the follow-up) of short dental implants of 98% and 94.1%, respectively. Some studies have suggested explanations for the reason for the increase in success rates, while influencing the final outcome, which can be grouped into: a) surgical technique; b) characteristics of the bone; c) dental implant design, and d) factors related to biomechanics¹¹.

CONCLUSION

In the present clinical case, a conservative technique was proposed for the use of short dental implants in the atrophic posterior upper maxilla zone, since large biomaterial volumes are not required for bone augmentation, thus avoiding autologous bone grafts with a higher rate of morbimortality, and traumatic techniques such as bone distractions. The geometric design of the dental implant surface of reduced height, under this placement technique, allows to shorten rehabilitation times for the benefit of the patient and their acceptance.

Declaration of conflict of interest: the authors declare that they have no conflicts of interest.

BIBLIOGRAPHIC REFERENCES

1. Lorrio Castro JM, Sierra Armas L, Lorrio Castro C, García Ávila I, Monsalve Guil L, Gómez Font R. Cirugía compleja en el tratamiento con implantes del maxilar superior. *Av Odontoestomatol.* 2017; 33(5): 213–20.
2. Reyes Doimi J, Aguirre Balseca G, Cáceres La Torre A. Colocación de implantes dentales en maxilar atrófico con técnica de cresta dividida y expansión del reborde. *Rev Odont Mex.* 2017; 21(3): 198–204. DOI: 10.1016/j.rodex.2017.09.007
3. Polis Yanes C, Domingo Mesengué M, López López J, Arranz Obispo C, Marí Roig A. Implantes dentales cortos en la rehabilitación de los maxilares atróficos: puesta al día. *Av Periodon Implantol.* 2017; 29(1): 23–30.
4. Barquero Cordero E, Contreras Molina I, Rodrigues Lopez Pereira Neto A, Oliveira de Souza J, Magalhães Benfatti C, Bianchini MA. Implante corto como alternativa para evitar los injertos óseos - Reporte caso clínico. *Acta Odontológica Venezolana.* 2012; 50(4). Disponible en: <https://www.actaodontologica.com/ediciones/2012/4/art-17/>
5. Velasco Ortega E, Medel Soteras R, García Méndez A, Ortiz García I, España López A, Núñez Márquez E. Sobredentaduras con implantes en pacientes geriátricos edéntulos totales. *Av Odontoestomatol.* 2015; 31(3): 161–72. DOI: 10.4321/S0213-12852015000300006
6. González Lagunas J. Alternativas a la elevación de seno maxilar: implantes cortos. *Rev Esp Cirug Oral y Maxilofac.* 2008; 30(6): 403–11.
7. Stern A, Green J. Sinus Lift Procedures: An Overview of Current Techniques. *Dent Clin North Am.* 2012; 56(1): 219–33. DOI: 10.1016/j.cden.2011.09.003
8. Thoma DS, Zeltner M, Hüsler J, Hämmerle C, Jung R. Supplement Working Group 4 - EAO CC Short Implants Versus Sinus Lifting with Longer Implants to Restore the Posterior Maxilla: A Systematic Review. *Clin Oral Implants Res.* 2015; 26(11): 154–69. DOI: 10.1111/clr.12615
9. Bustillo D, Zuloaga M. Elevación de piso de seno maxilar con técnica de ventana lateral y colocación simultánea de implantes: reporte de un caso. *Rev. Clin. Periodoncia Implantol. Rehabil. Oral.* 2017; 10(3): 159–62. DOI: 10.4067/S0719-01072017000300159
10. Anitua E. Implante corto unitario en sector posterior maxilar. Flujo digital y confección de corona mediante el uso de transepitelial unitario. *RO.* 2023; 26(1): 85–92. DOI: 10.29166/odontologia.vol25.n1.2023-e3616
11. Telleman G, Raghoobar GM, Vissink A, den Hartog L, Huddleston Slater JJ, Meijer HJ. A Systematic Review of the Prognosis of Short (<10mm) Dental Implants Placed in the Partially Edentulous Patient. *J Clin Periodontol.* 2011; 38(7): 667–76. DOI: 10.1111/j.1600-051X.2011.01736.x