



Clinical case

Trigeminal Neuralgia: Clinical Case Report and First Contact Management in Dentistry

Vianey Rios-Cruz¹, Esther Diana Carolina Ferraez-Castañeda²,
Israel Colín-Hernández³

¹ Odontóloga general de práctica privada, Universidad Autónoma de Guerrero.
<https://orcid.org/0009-0000-0112-0774>

² Cirujana Maxilofacial adscrita al Departamento de Odontología del Hospital Naval de Acapulco.
<https://orcid.org/0009-0003-1758-265X>

³ Especialista en endodoncia, adscrito al Departamento de Odontología del Hospital Naval de Acapulco.
<https://orcid.org/0000-0001-5020-7841>

Correspondence author:

Vianey Rios Cruz

E-mail: viane1399@gmail.com

Received: 8 September 2023

Accepted: 17 February 2025

Cite as:

Rios-Cruz V, Ferraez-Castañeda EDC, Colín-Hernández I. Neuralgia del trigémino: reporte de caso clínico y manejo de primer contacto en odontología [Trigeminal Neuralgia: Clinical Case Report and Management of First Contact in Dentistry]. *Rev Odont Mex.* 2025; 29(2): 30-37. DOI: 10.22201/fo.1870199xp.2025.29.2.86576

ABSTRACT

Introduction: Trigeminal neuralgia is characterized by paroxysmal pain, affecting the fifth cranial nerve with 3 branches with sensory and motor fibers. Its prevalence in the population is low but it is estimated that it affects more women than men. The diagnosis must be clinical, with a detailed clinical history and a precise physical examination. Their initial and follow-up treatments are mostly palliative, with pharmacological treatment as the line of first choice until surgical interventions. **Objective:** To create knowledge in the dentist about the initial diagnosis, clinical aspects, treatment, and management of a patient with symptoms of trigeminal neuralgia



and to recognize the important role played by being the first medical contact with the patient.

Case presentation: A 64-year-old male patient attended for emergency reasons referring pain in the upper right hemiarch due to third molar extraction, with a chronic degenerative history of systemic arterial hypertension. Upon intraoral examination, no apparent lesion was observed, not even radiographically. After performing a skull tomography and confirming the diagnosis by a specialist, it was decided to continue with pharmacological treatment. **Conclusion:** Trigeminal neuralgia is a rare disease and is generally diagnosed as toothache due to its proximity to dental structures, which is why the dentist occasionally performs unnecessary and irreparable treatments. A correct assessment and knowledge of the subject is very important for initial management and to avoid malpractice.

Keywords: Neuralgia, pain, trigeminal pain, diagnosis, dentist

INTRODUCTION

Trigeminal neuralgia (TN) is rare and is characterized by paroxysmal (sudden and intense) pain, which can last from seconds to minutes and affects one or more branches of the trigeminal nerve. Some patients describe it as a stabbing electric shock. Pain attacks may occur spontaneously or be triggered by stimuli, such as talking, chewing, swallowing, or tooth brushing¹⁻³.

Its etiology is not entirely clear, the most accepted theory points to the demyelination of the trigeminal nerve due to vascular compression at the ganglia⁴. Although there is a diversity of etiological elements that are discarded, it is a problem in neurology consultations due to the difficulty of diagnosis, since it is frequently confused with other diseases that are not of odontogenic origin such as postherpetic neuralgia, trigeminal autonomic headaches, and persistent idiopathic facial pain⁵. According to European studies performed in 2020, TN showed a prevalence of 0.16 to 0.3%, affecting more women (60%), than men (40%), between the ages of 53 to 57 years, and with a predilection for the right side of the face. It differs between studies, but it is estimated to be around a 3:1 ratio between women and men⁵⁻⁶.

In 2019, Latin American studies reported an average age of 53 years for classic trigeminal neuralgia and 43 years for secondary trigeminal neuralgia, although cases have been reported in infant patients under one year of age⁷⁻⁸. In patients with multiple sclerosis (MS), the incidence of TN is more likely than in the rest of the population, approximately 2% of them suffer from it overall⁹. The trigeminal nerve is the fifth cranial nerve, originating in the ganglion of Gasser. It is composed of sensory and motor fibers that divide into three main ones^{4,10}: ophthalmic branch V1, maxillary branch V2, and mandibular branch V3.

There are many pathophysiological hypotheses about the cause of TN origin, one of them describes that the intense pain is caused by the trigeminal ganglion cell somas deploying extensive discharges caused by the contact between one cell and another⁶. Another hypothesis proposed by Khawaja and Scrivani³ called the "*ignition hypothesis*" describing the paroxysmal characteristics of pain and structural alterations. According to the International Classification of Headache Disorders (ICHD)¹⁰, classic TN is caused by neurovascular compression, frequently by the superior cerebellar artery affecting 50% of the cases, thus acting as the origin of the nerve compression, and the other 25% of the cases are of venous onset⁹. Different studies

indicate that demyelination of the primary trigeminal afferent fibers in the dorsal root entry zone is a pathophysiological mechanism of trigeminal neuralgia².

The International Classification of Headache Disorders, third edition (ICHD-3)¹⁰ and the publications by the International Association for the Study of Pain (IASP)¹¹⁻¹² in 2018, divide trigeminal neuralgia into 5 types (Table 1)³⁻⁷. Trigeminal neuralgia usually starts abruptly after a syndrome called pre-neuralgic syndrome. It is known that the cause of TN is in the trigeminal nerve root, but the pain is often dispersed in the V2 or V3 branches, in combination or alone³. Patients with secondary trigeminal neuralgia are usually young and may have sensory loss in parts of the face and present bilateral pain manifested as an electrical discharge of paroxysmal pain caused by innocuous stimuli^{9,14}. Some patients may present with *blink reflex* changes⁷ although the clinical characteristics of the different TN are difficult to distinguish¹⁵.

Table 1.
Classification of the types of trigeminal neuralgia.

TYPES OF TRIGEMINAL NEURALGIA	CLINICAL FEATURES
Classic	The cause of the pain is not found, it can be attributed to neurovascular compression due to morphological changes originating in the nerve root.
Secondary	Related to an underlying cause or disease that may cause neuralgia. For example: multiple sclerosis, brain injury, stroke, or arteriovenous malformation.
Idiopathic	There are no diagnostic elements (neurophysiological tests or magnetic resonance imaging) to prove any type of disease or lesion to clarify the origin.
Painful	It can be classified into different types according to their cause, which can be attributed to herpes zoster.

Magnetic resonance imaging (MRI) is considered a diagnostic element¹⁴ since we can visualize neurovascular compression¹⁵. MRI in classic trigeminal neuralgia provides a better method of evaluating distortions, indentations, or displacements that may result from compression of a blood vessel⁶. Diffusion tensor imaging has been very relevant in recent years as it is very useful for the diagnosis of trigeminal neuralgia^{14,16}. Diagnosis is usually clinical by performing a very detailed clinical history and a precise physical examination. TN is most often misdiagnosed in the absence of objective evidence^{3,6}. The differential diagnosis includes: herpes zoster (the pain is continuous and is dispersed by the first trigeminal branch) which is attributed to painful TN, ipsilateral facial trauma, and odontalgia (due to the proximity of the branches of the trigeminal nerve with dental structures), thus making the dentist the main protagonist of the initial diagnosis. Severe pain is frequently confused with third-degree caries, pulpitis, periapical abscesses, and dental trauma^{2,7}. A detailed exploration of the face, neck, and oral cavity should be performed, identifying the trigger points (which when stimulated generate pain), to avoid unnecessary treatments such as dental extractions and root canal treatment in healthy teeth as a consequence of a poor diagnosis.

The diagnostic criteria according to ICHD-3 are: A. Recurrent paroxysm of unilateral or bilateral facial pain distributed in one or more divisions of the trigeminal nerve, without radiation and must meet criteria B and C; B. Pain characteristics: 1. Duration of a fraction of a second to 2 minutes, 2. Of severe intensity, 3. Analogous to an electric shock, shooting, stabbing, or acute; C. Precipitated by innocuous stimuli within the affected trigeminal distribution and D. Not better explained by another ICOP or ICHD-3 diagnosis⁷⁻⁸.

TN does not have a definitive cure, therefore, its treatment is based on reducing the intensity of pain or eliminating it^{4,5}. The first treatment of choice is carbamazepine, since it reduces pain by 70%, followed by oxcarbazepine (carbamazepine derivative)^{5-9,13-17}. Other antiepileptic drugs used are gabapentin, lamotrigine, phenytoin, baclofen, botulinum toxin A, lamotrigine, pimozone, ropivacaine and tizanidine. Botulinum toxin A is another treatment option to control other painful conditions such as headaches, migraines, occipital headaches, and post-herpetic neuralgia and has few side effects^{5,8}. Surgical procedures are considered when drugs are contraindicated or when the pain is so intense that it cannot be controlled with medication³. The performed surgical interventions are microvascular decompression (it is one of the first options in patients presenting classic and idiopathic neuralgia)¹, ablative procedures: rhizotomy with glycerol, radiofrequency thermocoagulation, balloon compression^{5,18}, stereotactic Gamma knife radiosurgery (non-invasive but destructive technique) and neurectomy⁶⁻¹⁶.

For this reason, the present case report aims to raise awareness among dentists about the initial diagnosis, clinical aspects, treatment and management of a patient with symptoms of trigeminal neuralgia so that they recognize the important role they play as the first medical contact with the patient.

CLINICAL CASE PRESENTATION

A 64-year-old male patient came to the emergency dentistry service due to severe pain in the right hemiface. He reported the onset of sudden pain before the consultation, so the dentist performed a simple extraction of the right upper third molar using a thin straight elevator and forceps #210, concluding the procedure without complications, analgesics were prescribed (ibuprofen 600 mg) without any improvement. The endodontic specialist performed vitality tests on the other teeth obtaining a negative result and finding asymptomatic, prescribed more analgesics and B complex without any change. The general dentist ruled out other probable lesions that were not clinically observed and made an interconsultation with the specialist in oral and maxillofacial surgery requesting an orthopantomography, thinking of a condition outside his competence and because this hospital does not have a neurology specialty as a first contact (Figure 1. A).

Upon interrogation, the patient denied any traumatic event in the facial or cephalic region, allergic or autoimmune diseases; he admitted positive to a chronic degenerative history of arterial hypertension controlled with irbesartan 150 mg every 24 hours with no relevance or relation to the current condition. The intraoral clinical examination of the upper arch showed adequate coloration and hydration of the integuments and mucous membranes, multiple teeth missing, dental abrasion of the right upper canine, central and left lateral incisors, as well as the left upper canine, in the midline of the palate there was an increase in volume with dimensions between 1.5 cm by 1.0 cm, indurated with a consistency similar to bone and clinically diagnosed as palatal torus, which for the moment no treatment was performed by decision of the patient. He did not accept the use of any type of removable prosthesis (Figure 1.B).

The orthopantomography showed bone resorption associated with multiple missing teeth, generalized dental abrasion, apical radiolucent area of the lower left first premolar and metallic restoration with second degree caries in the lower left first molar (Figure 1. C). None of the above was related to the area and the intense pain reported by the patient upon questioning.

The patient reported pain 10/10 on the Visual Analog Scale (VAS), based on the clinical practice guidelines of "pharmacological treatment of neuropathic pain in patients over 18 years

of age”, it was decided to start with a pharmacological scheme based on carbamazepine 200 mg every 12 hours for 15 days and only five doses of intramuscular hydroxocobalamin, eliminating the previously prescribed analgesic. After 15 days of treatment, the patient reported 5/10 VAS.

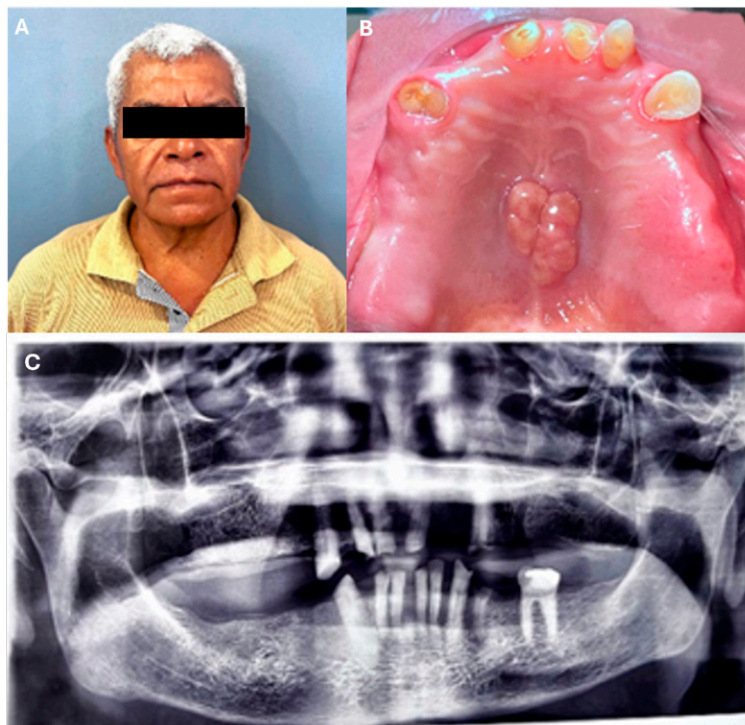


Figure 1. Initial findings. A. Frontal photograph. B. Occlusal intraoral photograph. C. Orthopantomography provided at the time of consultation.

Imaging studies of skull tomography and interpretation by a radiologist were performed and axial slices were done in a single phase from the base of the skull to the convexity. The following was observed: soft tissues and bony structures of the cranial vault with adequate density without fracture data, or lytic or blastic lesions (Figure 2. A). Both cerebral hemispheres showed normal morphology, with good differentiation of the gray-white matter, a neuralgia of central origin secondary to tumors was ruled out, observing discrete bilateral frontotemporal-parietal cortical atrophy (Figure 2. B). Other complementary laboratory studies were done including blood biometry, blood chemistry, and serum electrolytes with results within normal parameters. The specialist in neurology analyzed the studies and confirmed the diagnosis by adjusting the dose of carbamazepine since previously there was not an adequate result of pain control. After this 15-day period the patient reported an evolution to 0/10 in the VAS.

In this clinical case, the V2 trigeminal branch on the patient’s right side was affected, with paroxysmal pain that developed when talking, chewing, and brushing teeth and it was difficult to fall asleep as frequently described in the literature^{2,3}. According to the ICHD-3 and IASP, it was classified as a classic neuralgia, since the cause of the pain was not evident, but a factor associated with vascular decompression was found^{6,7}. Currently, after 6 months, he continues with the same pharmacological management and without presenting painful symptomatology.

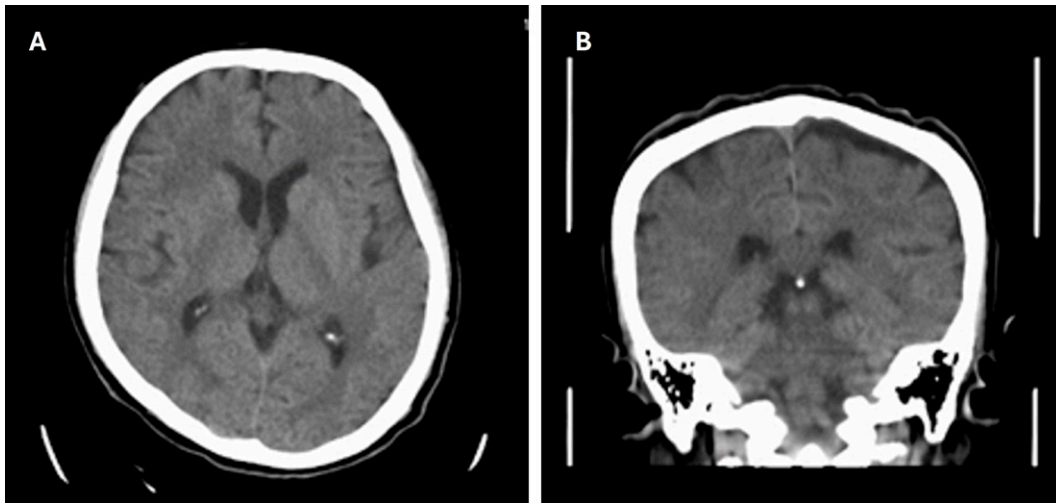


Figure 2. Tomographic images. A. Axial section. B. Coronal section with bilateral frontotemporal-parietal cortical atrophy.

DISCUSSION

In Mexico there are few articles about trigeminal neuralgia related to dentistry, the latest dated in 2018, in which the difficulty of its diagnosis is also exposed, since it is frequently confused with dental pain⁴, for such reason in the present article we try to encompass anatomy, classifications, diagnosis and treatments so far.

Carbamazepine is highly effective in reducing the pain symptoms of TN, showing an efficacy of up to 70% of treated patients, and is currently the initial pharmacological treatment of choice in our patients without adverse effects^{5,9}. As a chronic degenerative history, the patient suffers from controlled systemic arterial hypertension, which is not clear to be a risk factor that may cause microvascular decompression, but some authors consider it as a hypothesis¹⁹.

The patient's first contact dentist performed a simple dental extraction in the right upper third molar, for which he simply prescribed analgesics. The patient returned with pain in the right upper hemiarch, not finding the cause of the pain. Later on he was referred to the endodontist who as mentioned in the clinical case performed vitality tests obtaining negative results and continued prescribing more analgesics and adding B complex. In recent research, B complex is not considered as a first-choice treatment, but as an adjuvant in experimental and clinical tests, it was observed that vitamin B1 and B12 have pharmacological effects on axonal conduction both in analgesia and excitability, so their use would be justified²⁰. It is important to mention that, by ruling out pain of dental origin, dental extraction could have been avoided due to a bad diagnosis.

Although the definitive treatment will not be established by the dentist, he must establish TN among his differential diagnoses, after having ruled out any dental fracture, negative vitality tests, periapical abscesses, and temporomandibular joint disorders, thus avoiding malpractice. It is therefore important to be aware of the diagnostic criteria according to the ICHD-3 (International Classification of Headache Disorders, third edition) described in this manuscript. Performing a thorough examination and identifying trigger points that are activated by touch releasing intense pain, could have prevented the patient from going through different specialists.

CMP Forte Nucleus is also indicated in all types of neuronal affections, its function resides in the fundamental action of reestablishing the necessary conditions for correct nerve conduction, thus helping to reestablish the myelin sheath. In an exhaustive search, it was observed that CMP Forte nucleus has not presented any side effects or contraindications, only that there is an allergy to some of the components²¹. It is indicated for trigeminal neuralgia; however, it was not prescribed in this case because the endodontist had already prescribed complex B and the maxillofacial surgeon changed it to carbamazepine, the drug of first choice in treatments with TN.

CONCLUSION

Trigeminal neuralgia is an uncommon disorder of the fifth cranial nerve that presents itself in a very painful manner, severely affecting the daily life of patients who suffer from it. It is frequently diagnosed as odontalgia because it is very difficult to describe that the pain caused is due to TN, because it is not common and in the diagnostic elements used in the dental area such as radiographs it is not possible to observe if there is compression of any nerve, let alone to establish the definitive management. Sometimes the patient is completely healthy and has severe pain in dental areas, which may lead to suspecting a possible TN. In these cases, clinical examination is very important as well as palpating the sensitive areas (trigger points).

It is necessary to perform a thorough examination and to know the initial pharmacological therapeutic options for TN. If the pain does not subside with any other first choice analgesic, the teeth are in good condition and the orthopantomography does not show any abnormality in the dental structures, TN can be suspected and first choice management such as carbamazepine can be initiated.

BIBLIOGRAPHIC REFERENCES

1. Herta J, Schmied T, Loidl TB, Wang WT, Marik W, Winter F, et al. Microvascular decompression in trigeminal neuralgia: predictors of pain relief, complication avoidance, and lessons learned. *Acta Neurochir (Wien)*. 2021; 163(12): 3321-3336. DOI: 10.1007/s00701-021-05028-2
2. Allam AK, Sharma H, Larkin MB, Viswanathan A. Trigeminal neuralgia: Diagnosis and treatment. *Neurol Clin*. 2023; 41(1): 107-121. DOI: 10.1016/j.ncl.2022.09.001
3. Khawaja SN, Scrivani SJ. Trigeminal neuralgia. *Dent Clin North Am*. 2023; 67(1): 99-115. DOI: 10.1016/j.cden.2022.07.008
4. Grin EJ, Grin P, Rocha Navarro ML. Neuralgia del trigémino: un caso clínico. *Rev ADM*. 2018; 75(3): 164-167. Disponible en: <https://www.medigraphic.com/pdfs/adm/od-2018/od183i.pdf>
5. Gerwin R. Chronic facial pain: Trigeminal neuralgia, persistent idiopathic facial pain, and myofascial pain syndrome – an evidence-based narrative review and etiological hypothesis. *Int J Environ Res Public Health*. 2020; 17(19): 7012. DOI: 10.3390/ijerph17197012
6. Bendtsen L, Zakrzewska JM, Heinskou TB, Hodaie M, Leal PRL, Nurmikko T, et al. Advances in diagnosis, classification, pathophysiology, and management of trigeminal neuralgia. *Lancet Neurol*. 2020; 19(9): 784-796. DOI: 10.1016/S1474-4422(20)30233-7

7. Latorre G, González-García, García-Ull J, González-Oria, Porta-Etessam J, Molina FJ, *et al.* Diagnosis and treatment of trigeminal neuralgia: Consensus statement from the Spanish Society of Neurology's Headache Study Group. *Neurologia (Engl Ed)*. 2023; 38(Suppl 1): S37-S52. DOI: 10.1016/j.nrleng.2023.04.005
8. Marín-Medina D, Gámez-Cárdenas S. Neuralgia del trigémino: aspectos clínicos y terapéuticos [Trigeminal neuralgia: clinical and therapeutic aspects]. *Acta Neurol Colomb*. 2019; 35(4): 193-203. DOI: 10.22379/24224022267
9. Araya EI, Claudino RF, Piovesan EJ, Chichorro JG. Trigeminal neuralgia: Basic and clinical aspects. *Curr Neuropharmacol*. 2020; 18(2): 109-119. DOI: 10.2174/1570159X17666191010094350
10. International Headache Society. *International classification of headache disorders*. 3 ed. London: International Headache Society, 2025. Disponible en: <https://ihs-headache.org/wp-content/uploads/2025/04/ICHD-3-Cephalalgia-2018-issue-1.pdf>
11. Merskey H, Bogduk N (eds.). *Classification of chronic pain*. 2 rev. ed. Washington, D.C.: IASP Press, 2012. Disponible en: <https://www.iasp-pain.org/publications/free-ebooks/classification-of-chronic-pain-second-edition-revised/>
12. International Association for the Study of Pain. *Multidisciplinary Pain Center Development Manual*. Washington, D.C.: International Association for the Study of Pain, 2021. Disponible en: https://www.iasp-pain.org/wp-content/uploads/2021/11/IASP-PainManagementCenter_toolkit.pdf
13. Sayaci EY, Kahilogullari G, Comert A, Morali Guler T, Guner YE, Korkmaz AC, *et al.* Morphology of the trigeminal ganglion: anatomical structures related to trigeminal radiofrequency rhizotomy. *Acta Neurochir (Wien)*. 2022; 164(6): 1551-1566. DOI: 10.1007/s00701-022-05160-7
14. Ruscheweyh R, Lutz J, Mehrkens JH. Trigeminalneuralgie: Moderne Diagnostik und Therapie. *Schmerz*. 2020; 34(6): 486-494. DOI: 10.1007/s00482-020-00496-4
15. Cruccu G, Di Stefano G, Truini A. Trigeminal neuralgia. *N Engl J Med*. 2020; 383(8): 754-762. DOI: 10.1056/NEJMr1914484
16. Buckcanan Vargas A, Mata Fuentes M, Fonseca Artavia K. Neuralgia del trigémino. *Med Leg Costa Rica*. 2020; 37(1): 130-137. Disponible en: https://www.scielo.sa.cr/scielo.php?pid=S1409-00152020000100130&script=sci_abstract&tlng=es
17. Bridwell RE, Brown S, Clerkin S, Birdsong S, Long B. Neurologic toxicity of carbamazepine in treatment of trigeminal neuralgia. *Am J Emerg Med*. 2022; 55: 231.e3-231.e5. DOI: 10.1016/j.ajem.2022.01.044
18. Yan C, Zhang Q, Liu C, Yang J, Bian H, Zhu J, *et al.* Efficacy and safety of radiofrequency in the treatment of trigeminal neuralgia: a systematic review and meta-analysis. *Acta Neurol Belg*. 2022; 122(4): 1019-1030. DOI: 10.1007/s13760-021-01654-w
19. Eide PK. Familial occurrence of classical and idiopathic trigeminal neuralgia. *J Neurol Sci*. 2022; 434: 120101. DOI: 10.1016/j.jns.2021.120101
20. Tirado Amador LR, Torres Osorio L, Arce Vanegas JA. Neuralgia trigeminal y algunas consideraciones en la práctica clínica de la odontología. *Rev Nac Odontol*. 2019; 15(29): 1-15. DOI: 10.16925/2357-4607.2019.02.06
21. Covarrubias-Gómez A, Guevara-López UM, Cantú-Brito C, Nuche-Cabrera E, Guajardo-Rosas JA. Recomendaciones de práctica clínica para el manejo del dolor neuropático: Grupo de interés en dolor neuropático de la Asociación Mexicana para el Estudio y Tratamiento del Dolor. *Rev Mex Anest*. 2015; 38(4): 264-276. Disponible en: <https://www.medigraphic.com/cgi-bin/new/resumen.cgi?IDARTICULO=62435>