



## Warthin's tumor: An experience of the General Hospital «Calixto García». Havana, Cuba

### *Tumor de Warthin: Una experiencia del Hospital «General Calixto García». La Habana, Cuba*

Alejandro Donohue Cornejo,\* Ana Dolores Mori Estévez,<sup>§</sup> Guillermo Sánchez Acuña,<sup>||</sup> Dalia Abril Guzmán Gastelum,\* Raúl A Sánchez Rubio Carrillo,<sup>¶</sup> Daniel Alberto Constandse Cortez,\* Luis Alberto Gaitán Cepeda\*\*

#### ABSTRACT

**Background:** Warthin's tumor, a benign tumor of the salivary glands, was first described by Dr. Hildebrand in 1896. It was later extensively described by Dr. Warthin in 1929. It represents the second most frequent neoplasia found in the salivary glands. It constitutes 10% of all salivary glands tumors. **Methods:** A salivary gland retrospective study was conducted at the Pathological Anatomy Department of the «Calixto García» Hospital in Havana, Cuba. The study was conducted in the period comprised between January 2001 and December 2008. Two oral pathology experts re-diagnosed the cases following diagnostic criteria proposed in 2005 by the World Health Organization (WHO). **Results:** Out of 159 studied cases, 113 (71.1%) were benign tumors (48 male patients, 65 female, average age 50.8 [± 15], age range 20-80 years). Most frequently found tumor was pleomorphic adenoma, which counted 77 cases (68.1%) followed by Warthin's tumor with 33 cases (20.7%) of all included salivary glands tumors and 29.2% of benign tumors. **Conclusions:** The present study revealed the fact that Warthin's tumor proportion is among the highest reported in recent years in scientific literature.

**Key words:** Warthin's tumor, epidemiology, Cuba.

**Palabras clave:** Tumor de Warthin, epidemiología, Cuba.

#### INTRODUCTION

Warthin's tumor (WT) is a benign tumor of the salivary glands also known as lymphomatous papillary cystadenoma or adenolymphoma.<sup>1,2</sup> Dr. Hildebrand first reported it in 1895, at a later date in 1929 Dr. Warthin described it extensively.<sup>1-3</sup> WT is the salivary gland second most frequent neoplasia<sup>4,5</sup> and represents 10% of all salivary gland tumors.<sup>4</sup> It predominantly appears at the 5<sup>th</sup> and 7<sup>th</sup> decades of life, exhibits a strong predisposition towards male gender with a male-female ratio of 3:1. WT appears quasi exclusively at the superficial lobe of the parotid gland. Tumors can be bilateral (synchronous tumors), or multiple.<sup>6</sup> Years later, a second or subsequent third

#### RESUMEN

**Antecedentes:** El tumor de Warthin –tumor benigno de glándulas salivales– fue reportado por primera vez en 1895 por Hildebrand y posteriormente en 1929 Warthin lo describió ampliamente. Es la segunda neoplasia más frecuente de las glándulas salivales, representando el 10% de todos los tumores de glándulas salivales. **Métodos:** Se realizó un estudio retrospectivo de tumores de glándulas salivales del Departamento de Anatomía Patológica del Hospital «Calixto García» de La Habana, Cuba, durante el periodo de enero del 2001 a diciembre del 2008. Los casos fueron rediagnosticados por dos expertos en patología bucal, basados en los criterios diagnósticos propuestos por la Organización Mundial de la Salud en el 2005. **Resultados:** De 159 casos, 113 (71.1%) fueron tumores benignos (48 hombres, 65 mujeres; promedio de edad 50.8 [± 15], rango de edad 20-80 años). El tumor más frecuente fue el adenoma pleomorfo con 77 casos (68.1%), seguido del tumor de Warthin con 33 casos, que constituyen el 20.7% del total de tumores de glándulas salivales incluidos y el 29.2% del total de los tumores benignos. **Conclusiones:** En nuestro estudio, la proporción del tumor de Warthin está dentro de las más altas, acorde a lo reportado en la literatura de los últimos años.

lesion can appear (metachronous tumors).<sup>7,8</sup> From the microscopic perspective, WT is a tumor composed

\* Oral Pathology Laboratory, Stomatology Department, Biomedical Sciences Institute, University of Ciudad Juárez, Mexico.

§ Pathological Anatomy Department, «Calixto García» Hospital. Havana, Cuba.

|| Head and Neck Surgery Department, «Calixto García» Hospital. Havana, Cuba.

¶ School of Dentistry, Mexicali Campus, Baja California University.

\*\* Experimental and Clinical Pathology Laboratory, Graduate and Research School, National School of Dentistry, National University of Mexico (UNAM).

of cystic structures with papillary projections coated with a double epithelial layer on a lymphoid stroma which can even represent true germinal centers.<sup>4</sup> Luminal epithelium is composed of cell columns with apical or central ovoid nucleus, generally in a palisade formation. Cytoplasm is finely granular and eosinophilic. Some tumors exhibit disperse mucous cells which can be squamous cells or even sebaceous cells. Stroma contains a dense component of non-neoplastic small lymphocytes which form germinal centers and mantle zone.<sup>9</sup>

In recent years, it has been suggested that demographic profiles of certain head and neck tumors exhibit a tendency to change.<sup>7,10</sup> There is specifically an important change in the male: female WT ratio. Affected female numbers increased with or without increase of male cases.<sup>11</sup> With the aim of contributing to clarify this suggestion, clinical-epidemiological characteristics are reported of a retrospective WT series coming from a given Cuban population.

#### MATERIAL AND METHODS

A salivary gland tumors retrospective study was conducted based on the files of the Pathological Anatomy Department of the «Calixto García» Hospital in Havana, Cuba. To that effect all reports of salivary gland tumors during the period ranging from January 2001 to December 2008 were identified and selected. Out of selected cases, the following were excluded: cases which lacked histological slides, cases lacking sufficient biological material to be cut at 5  $\mu$ m and be stained with hematoxylin and eosin staining technique. For research purposes, included cases were independently observed and re-diagnosed. This procedure was conducted by two oral pathology experts (ADC/LAGC) based on diagnosis criteria proposed in 2005 by the World Health Organization (WHO).<sup>12</sup> Cases presenting discrepancy between both observers were discarded from the analysis.

The following data were taken from the medical files of the Histopathology Department: age, gender and tumor site. With data thus collected, a tailor-made data base was built. Central tendency measures were obtained as well as relative frequency with respect to gender, tumor site and age. Differences or associations among demographic variables were established through t Student test ( $p < 0.05_{IC\ 95\%}$ ). Statistical package SPSS13.0® was used to this effect.

Out of a database with 85,000 files, 236 salivary gland tumor cases were selected. Out of these 236 cases, 33 were discarded due to lack of suitable biological material. Thus, 203 cases were studied.

After analysis and observation, 159 cases fulfilled the inclusion criterion of exhibiting salivary gland neoplasia diagnosis. The 44 non included cases were eliminated for the following reasons: not being tumor lesion, exhibiting diagnosis of stromal-origin neoplasia, or due to discrepancies in the observations of the examiners.

#### RESULTS

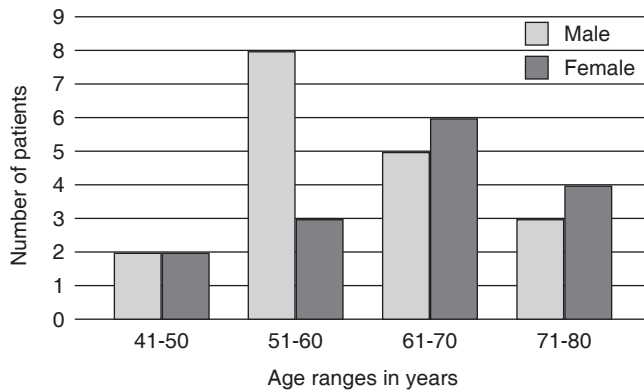
The 159 confirmed salivary gland epithelial-originated tumors represented, with respect to all files, a prevalence of 0.18%. Total age average of the sample was 54.3 cases ( $\pm 15.4$ ), age range was 20 to 86 years. Out of the 159 cases, 71 (44.6%) were found in males (average age at the time of diagnosis was 55.1 years; SD  $\pm 16.4$ , age range was 20-86 years) and 88 (55.4%) were found in females (age average 53 years, SD  $\pm 14.51$ , age range 22-85). Age difference between both genders was not statistically significant ( $p < 0.05$ ). The most prevalent age peak was located between the sixth and seventh decade of life.

Out of the 159 cases, 113 (71%) were benign tumors (48 males, 65 females, age average 50.8 [ $\pm 15$ ], age range 20-80 years). When studying benign tumors (113 = 100%) the distribution of frequency per diagnosis revealed that the most frequent tumor was pleomorphic adenoma, with 77 cases (68.1%), followed by Warthin's tumor with 33 cases. This datum was noteworthy since it represented one of the highest proportions reported in scientific literature.

Thus, the 33 WT cases represented 20.7% of the total included salivary gland tumor numbers as well as 29.2% of total benign tumors. Age average at the moment of diagnosis of this neoplasia was 61.7 years; incidence peak was found in the sixth decade of life. As far as gender distribution went, 18 cases (54.5%) were found in males and 15 cases (45.5%) were found in females (Figure 1).

This association found between males and WT was not statistically significant ( $p < 0.05$ ). All cases of WT were unilateral and were located at the parotid gland.

Histologically, all WT cases exhibited the characteristics described in scientific literature. Briefly, neoplasia circumscribed by a capsule, where the cystic areas walls were lined with a double row of oncocyctic cells. The luminal layer of the oncocytes exhibited a columnar shape, supported by a discontinuous basal layer of basal oncocytes. The nuclei of luminal cells was arranged in a palisade pattern towards the free side, while basal cells presented a small, central, round or ovoid nucleus, with conspicuous nucleoli. Oncocyctic cells, presented a granular and eosinophilic cytoplasm, and were separated from the stroma by



**Figure 1.** The greatest number of cases was found in the 6<sup>th</sup> and 7<sup>th</sup> decades of life. Males exhibited predominance in the 6<sup>th</sup> decade and females in the 7<sup>th</sup>.

a basal membrane. Supporting tissue was lymphoid tissue, composed of non-neoplastic lymphocytes, diffusely arranged, usually containing germinal centers.

## DISCUSSION

The present retrospective clinical study described WT clinical-epidemiological characteristics in a Cuban population. In order to identify WT, 159 salivary gland tumor cases were analyzed; out of which 71% were benign tumors. These data were very similar to those reported in China (67.5%) and Zimbabwe (68%).<sup>13,14</sup> Nevertheless, they were noticeably higher than those reported by Li et al. (59.7%) in Occidental China.<sup>15</sup>

In the present study, WT constituted 29.2% of the total number of benign tumors. They represented the second most frequent benign neoplasia. Even though most scientific literature reports concur, their prevalence varied significantly. In the USA a 5.3% relative frequency was reported;<sup>12</sup> this concurred with occidental China (7%),<sup>15</sup> India (8.1%)<sup>16</sup> and Brazil (8.2%).<sup>17</sup> Higher relative frequencies have been reported in Romania<sup>8</sup> (11.6%), United Kingdom<sup>18</sup> (14.4%), Sri Lanka<sup>19</sup> (16.6%) and oriental China<sup>13</sup> (20.2%). Our results revealed even higher proportions: 29.4%, these data were very similar to those reported in Denmark<sup>20</sup> (27%) and Pennsylvania, USA<sup>12</sup> (30%) (Table I). Thus, after literature review, to our knowledge, the present report reveals the fact that Cuban population presented the second highest proportion of WT in the world. This observed high frequency might be attributed to high tobacco consumption in Cuba, which in cities like Havana and Pinar del Río reach a 41% prevalence in general population.<sup>21</sup>

Even though Warthin tumor's etiology is still unknown, a strong association between tobacco use and WT has been established.<sup>9,12,22</sup> Epidemiological evidence is overwhelming.<sup>23</sup> More cases of bilateral WT have been reported in heavy smokers ( $\geq 20$  cigarettes a day according to WHO) than in non-smokers.<sup>24</sup> The continuous irritation of the ductal epithelium due to tobacco smoke has been proposed as a carcinogenic mechanism.<sup>8,23</sup> This association between tobacco consumption and WT could also justify its predominance in males and low predominance in females in countries where there

**Table I.** Frequency of Warthin's tumor in recent years.

Name	Year	Country	Total benign tumors	Warthin Tumors	
				n	%
Poulsen P et al. <sup>20</sup>	1987	Denmark	116	32	27.50
Monk Js <sup>43</sup>	1992	Pennsylvania, USA	138	42	30.40
García-Roco <sup>38</sup>	2003	Cuba	74	19	25.60
Demetrio Larrain y cols. <sup>39</sup>	2005	Chile	92	10	10.86
FA Ito <sup>40</sup>	2005	Brazil	335	42	12.50
Li Long-Jiang et al. <sup>15</sup>	2008	China	2,069	151	7.30
AV James et al. <sup>18</sup>	2008	United Kingdom	481	34	4.60
O Ochicha <sup>41</sup>	2010	Nigeria	44	0	0.00
Z Tian et al. <sup>13</sup>	2010	China	4,743	961	20.26
I Luksic <sup>42</sup>	2011	Croatia	383	87	22.80
A Donohue et al.	2012	Cuba	113	33	29.20

Prevalence reported in the present study is the second highest, second only to the 30.4% figure reported for Pennsylvania.

is low rate of smokers.<sup>19</sup> For instance, in Cuba, according to the national survey of risk factors, it was calculated that in 2001 there were 2,047,714 smokers aged 17 years and over. This represented 31.9% prevalence, which was lower than the 68.9% reported in 1978. These figures, even though lower, are still very high.<sup>25</sup> Cuba, Denmark<sup>26</sup> and China<sup>27</sup> are countries with high prevalence of Warthin's tumor. This concurs with their high smoking index, 45 and 63% respectively. Besides tobacco use, many theories with respect to its etiology have been proposed: **Hormonal:** in view of its high incidence in males, nevertheless, in the development of salivary gland tumors the significance of the role played by sexual hormones remains unclear.<sup>28</sup> **Embryonic:** which proposes that this tumor develops from salivary ducts inclusions in lymph nodes, after the embryonic development of the parotid gland, due to this it should be considered a hamartoma.<sup>8,29</sup> **Infectious:** especially viral, associated to Epstein-Barr virus and cytomegalovirus, recently the role of the type 8 human herpes virus (HHV) has been suggested; nevertheless, the role of this virus in the development of Warthin's tumor has not been totally clarified.<sup>30</sup>

Apart from its etiology, two hypotheses have been proposed with respect to its behavior: could it be a reactive lesion or a true neoplasia? Recent molecular evidence has identified a polyclonal epithelial component. This would suggest the fact that WT might be a hyperplastic reactive entity.<sup>31,32</sup> In addition to all the aforementioned, there is preliminary evidence of the presence of genetic damage, characterized by chromosomal translocation, this is associated to the generation of a new oncogenic fusion (CRTC1-MAML2). This supports the theory of considering WT as true neoplasia.<sup>31</sup> Thus, available information suggests that WT could be a group of lesions exhibiting pathogenesis which could be heterogeneous, polyclonal, possibly reactive or clonal, and doubtlessly neoplastic, but with identical morphology.<sup>31</sup> In the present study it would have been desirable to determine possible chromosomal anomalies, nevertheless, due to logistic matters, this could not be achieved.

WT histogenesis and consequent morphological image have equally been justified by means of two hypotheses: one proposes the development of heterotopic salivary ductal tissue development trapped within lymph nodes, either within or peri- or intra-parotideal; the other theory proposes intra-glandular ductal proliferation which would induce an intense lymphocytic infiltration.<sup>9,31</sup> Nevertheless,

the fact that these lesions reach a certain size and remain static, and additionally are multiple or bilateral, cannot be explained by neither of both hypotheses.

It has been reported that WT predominantly appears in the 5<sup>th</sup> and 7<sup>th</sup> decades of life.<sup>13,17,19</sup> Our general results concur with this information, although age average is slightly lower: 60.9 years. With respect to gender, WT has been associated to males. In a study conducted in Sri Lanka, in a series of salivary gland epithelial tumors, all WT cases were found in male patients.<sup>19</sup> In eastern China, the male-female ratio was 11:1. In the present report, male-female ratio was 1:1. In recent years, an increase of WT has been observed in female patients. In 1953 the male-female ratio was 10:1.<sup>33</sup> In 1979 a male-female ratio of 1.5:1 was found.<sup>34</sup> In 1983 the reported ratio was 1:1,<sup>35</sup> in 1994 the ratio was 2.2:1 and in 1996 the ratio was 1:1.<sup>36</sup> Recent reports reveal a 2:1 M:F ratio.<sup>11</sup> Once more, this fact could be justified by the fact that a decrease in male smokers has been reported alongside with an increase of female smokers.<sup>8,37</sup>

It has been reported that WT could be associated to ethnicity, since it is very rare among African Americans.<sup>37</sup> The high WT frequency found in the present paper does not support that suggestion, since predominant ethnicity in Cuban population is of African ascent.

WT predominant onset location is the parotid gland, specifically the superficial lobule<sup>9,13,17,19</sup> although, sporadically, they have been reported in the sub-mandibular gland and even in accessory salivary glands.<sup>17</sup> In the present study all tumors were located in the parotid gland. It is necessary to mention that the General Hospital «Calixto García», Havana, Cuba, is a concentration hospital, where patients with head and neck lesions are referred, so, intra-oral lesion cases are scarce. WT can occur bilaterally, or a second or third tumor can appear simultaneously in the same gland, additionally, a second or third lesion can appear years later.<sup>24,29</sup> Although determination of these data might have been interesting, it was not possible to establish.

Treatment of choice in most cases is a superficial parotidectomy. Recurrence is rare, but that event would probably represent a new neoplasia (metachronous tumors) originated from residual glandular elements. Complications of parotidectomy include among others: transitory paralysis or paresis of the facial nerve, seroma, Frey's syndrome.<sup>22</sup> Long term patient follow-up is deemed advisable due to the possibility of metachronous tumors development.<sup>22</sup>

## CONCLUSION

Most results elicited in this study on clinical-demographic characteristics of WT were similar to those reported in scientific literature. Nevertheless, there are geographical variations with respect to relative frequency, and ethnicity (including African-Americans). Results equally confirm increase in cases found in female patients.

## REFERENCES

- Yoshimura Y, Gabka J. Clinical evaluation of Warthin's tumor. An analysis of 43 cases. *Int J Oral Surg.* 1979; 8: 8-17.
- Ethunandan M, Pratt CA, Higgins B, Morrison A, Umar T, Macpherson DW et al. Factors influencing the occurrence of multicentric and 'recurrent' Warthin's tumor: a cross sectional study. *Int J Oral Maxillofac Surg.* 2008; 37: 831-834.
- Sánchez E, Meléndez B, Revelles H, Védia J, Murga C. Tumor de Warthin bilateral. *ORL-Dips.* 2005; 32: 47-50.
- Aguirre JM, Echebarría MA, Martínez-Conde R, Rodríguez C, Burgos JJ, Rivera JM. Warthin tumor. A new hypothesis concerning its development. *Oral Surg Oral Med Oral Pathol Oral Radiol Endod.* 1998; 85: 60-63.
- Yerli H, Avci S, Aydin E, Arikan U. The metaplastic variant of Warthin tumor of the parotid gland: dynamic multislice computerized tomography and magnetic resonance imaging findings with histopathologic correlation in a case. *Oral Surg Oral Med Oral Pathol Oral Radiol Endod.* 2010; 109: e95-e98.
- Teymoortash A, Krasnewicz A, Werner JA. Clinical features of cystadenolymphoma (Warthin's tumor) of the parotid gland: a retrospective comparative study of 96 cases. *Oral Oncol.* 2006; 42: 569-573.
- Mejía-Velázquez CP, Durán-Padilla MA, Gómez-Apo E, Quezada-Rivera D, Gaitán-Cepeda LA. Tumors of the salivary gland in Mexicans. A retrospective study of 360 cases. *Med Oral Patol Oral Cir Bucal.* 2012; 17: e183-e189.
- Faur A, Lazăr E, Cornianu M, Dema A, Vidita CG, Gălușcan A. Warthin tumor: a curious entity case reports and review of literature. *Rom J Morphol Embryol.* 2009; 50: 269-273.
- Ellis GL. Lymphoid lesions of salivary glands: malignant and benign. *Med Oral Patol Oral Cir Bucal.* 2007; 12: e479-e485.
- Gaitán-Cepeda LA, Peniche-Becerra AG, Quezada-Rivera D. Trends in frequency and prevalence of oral cancer and oral squamous cell carcinoma in Mexicans. A 20 years retrospective study. *Med Oral Patol Oral Cir Bucal.* 2011; 16: e1-e5.
- Cardoso SV, do Nascimento-Souza KC, de Faria PR, Lima RA, Nascimento MF, Eisenberg AL et al. Warthin's tumor at the Brazilian National Cancer Institute: additional evidence of homogeneous sex prevalence and association with other neoplasms. *ORL J Otorhinolaryngol Relat Spec.* 2008; 70: 339-343.
- Barnes L. *Pathology and genetics of head and neck tumors.* Lyon, France: World Health Organization, International Agency for Research on Cancer; 2005.
- Tian Z, Li L, Wang L, Hu Y, Li J. Salivary gland neoplasms in oral and maxillofacial regions: a 23-year retrospective study of 6,982 cases in an eastern Chinese population. *Int J Oral Maxillofac Surg.* 2010; 39: 235-242.
- Chidzonga MM, López-Pérez VM, Portilla-Álvarez AL. Salivary gland tumours in Zimbabwe: report of 282 cases. *Int J Oral Maxillofac Surg.* 1995; 24: 293-297.
- Li LJ, Li Y, Wen YM, Liu H, Zhao HW. Clinical analysis of salivary gland tumor cases in west China in past 50 years. *Oral Oncol.* 2008; 44: 187-192.
- Patil K, Mahima VG, Kalia S. Papillary cystadenomalymphomatousum: case report and review of literature. *Indian J Dent Res.* 2005; 16: 153-158.
- de Oliveria FA, Barroso-Duarte EC, Texeira-Taveira C, Abreu-Máximo A, Carvalho de Aquino E, de Cássia-Alencar R et al. Salivary gland tumor: a review of 599 cases in a Brazilian population. *Head Neck Pathol.* 2009; 3: 271-275.
- Jones AV, Craig GT, Speight PM, Franklin CD. The range and demographics of salivary gland tumours diagnosed in a UK population. *Oral Oncol.* 2008; 44: 407-417.
- Tilakaratne WM, Jayasooriya PR, Tennakoon TMPB, Saku T. Epithelial salivary tumors in Sri Lanka: a retrospective study of 713 cases. *Oral Surg Oral Med Oral Pathol Oral Radiol Endod.* 2009; 108: 90-98.
- Poulsen P, Jørgensen K, Grøntved A. Benign and malignant neoplasms of the parotid gland: incidence and histology in the Danish County of Funen. *Laryngoscope.* 1987; 97: 102-104.
- Chávez-Martínez FJ, Romero-Pérez T, González-Marinello S, Lence-Anta JJ, Santos-Martínez T. Riesgos de morir por cáncer en Cuba. *Rev Cubana Oncol.* 1997; 13: 5-11.
- Chedid HM, Rapoport A, Aikawa KF, Menezes-Ados S, Curioni OA. Warthin's tumor of the parotid gland: study of 70 cases. *Rev Col Bras Cir.* 2011; 38: 90-94.
- Sadetzki S, Oberman B, Mandelzweig L, Chetrit A, Ben-Tal T, Jarus-Hakak A et al. Smoking and risk of parotid gland tumors: a nationwide case-control study. *Cancer.* 2008; 112: 1974-1982.
- Peter-Kluschmann J, Wittekindt C, Florian-Preuss S, Al Attab A, Schroeder U, Guntinas-Lichius O. High risk for bilateral Warthin tumor in heavy smokers review of 185 cases. *Acta Otolaryngol.* 2006; 126: 1213-1217.
- [acceso 14 de marzo de 2013]. Available in: [www.ecured.cu/index.php/Tabaquismo\\_en\\_Cuba](http://www.ecured.cu/index.php/Tabaquismo_en_Cuba).
- Graham H. Smoking prevalence among women in the European community 1950-1990. *Soc Sci Med.* 1996; 43: 243-254.
- Yang G, Fan L, Tan J, Qi G, Zhang Y, Samet JM et al. Smoking in China: findings of the 1996 National Prevalence Survey. *JAMA.* 1999; 282: 1247-1253.
- Teymoortash A, Lippert BM, Werner JA. Steroid hormone receptors in parotid gland cystadenolymphoma (Warthin's tumour). *Clin Otolaryngol Allied SCI.* 2001; 26: 441-446.
- Colella G, Biondi P, Itró A, Compilato D, Campisi G. Warthin's tumor distribution within the parotid gland. A feasible etiologic source from lymph nodal tissue. *Minerva Stomatol.* 2010; 59: 245-249.
- Dalpa E, Gourvas V, Baritaki S, Miyakis S, Samaras V, Barbatis C et al. High prevalence of human herpes virus 8 (HHV-8) in patients with Warthin's tumors of the salivary gland. *J Clin Virol.* 2008; 42: 182-185.
- O'Neill ID. New insights into the nature of Warthin's tumour. *J Oral Pathol Med.* 2009; 38: 145-149.
- Teymoortash A, Werner JA, Moll R. Is Warthin's tumour of the parotid gland a lymph node disease? *Histopathology.* 2011; 59: 143-145.
- Foote FW, Frazell EL. Tumors of the major salivary glands. *Cancer.* 1953; 6: 1065-1133.
- Eveson JW, Cawson RA. Warthin's tumor (cystadenolymphoma) of salivary glands. A clinicopathologic investigation of 278 cases. *Oral Surg Oral Med Oral Pathol.* 1986; 61: 256-262.
- Kennedy TL. Warthin's tumor: a review indicating no male predominance. *Laryngoscope.* 1983; 93: 889-891.

36. Sato T, Morita Y, Hamamoto S, Noikura T, Kawashima K, Matsune S et al. Interpretation of scintigraphy of papillary cystadenoma lymphomatosum (Warthin's tumor) on the basis of histopathologic findings. *Oral Surg Oral Med Oral Pathol Oral Radiol Endod.* 1996; 82: 101-107.
37. Monk JS Jr, Church JS. Warthin's tumor. A high incidence and no sex predominance in central Pennsylvania. *Arch Otolaryngol Head Neck Surg.* 1992; 118: 477-478.
38. García OR. Tumores de glándulas salivales. Su comportamiento en 10 años de trabajo. (1993-2002); *Rev Cubana Estomatol.* 2003; 40 (3).
39. Larraín DC, Madrid A, Capdeville F, Ferrada C. Tumores de glándulas salivales: hallazgos histopatológicos en 168 pacientes. Salivary gland tumors. Histopathological findings in 168 patients. *Rev Chilena de Cirugía.* 2005; 57 (5): 373-378.
40. Ito FA, Ito K, Vargas PA, Almeida OP, Lopes MA. Salivary gland tumors in a Brazilian population: a retrospective study of 496 cases. *Int J Oral Maxillofac Surg.* 2005; 34: 533-536.
41. Ochicha O, Malami S, Mohammed A, Atanda A. A histopathologic study of salivary gland tumors in Kano, northern Nigeria. *Indian Journal of Pathology and Microbiology.* 2009; 52 (4): 473-476.
42. Luksic I, Virag M, Manojlovic S, Macan D. Salivary gland tumors: 25 years of experience from a single institution in Croatia. *Journal of Cranio-Maxillo-Facial Surgery.* 2012; 40: 75-81.
43. Monk JS Jr, Church JS. Warthin's tumor. A high incidence and no sex predominance in central Pennsylvania. *Arch Otolaryngol Head Neck Surg.* 118: 477-478.

Mailing address:

**Dr. Alejandro Donohue Cornejo**

E-mail: adonohue@uacj.mx