



## Intrinsic tooth whitening using thermo-catalytic technique. Clinical case report

### *Blanqueamiento dental intrínseco utilizando técnica termo-catalítica. Presentación de un caso clínico*

Norberto Juárez Broom,\* Santiago Andaracua García,§ Diana Karina Barrera Zamacona<sup>||</sup>

#### ABSTRACT

A 20 year old female patient attended the dental hospital of the Regional Military Hospital, Guadalajara, Jalisco. The patient's complaint was tooth discoloration. Exploration revealed dyschromia in the upper central right incisor. Sensitivity tests elicited negative results, radiographic examination revealed lack of radio-lucid areas. Emitted diagnosis was pulp necrosis. Root canal treatment was conducted in one single visit. Intra-coronary whitening with thermo-catalytic technique was achieved at a later date. Clinical and radiographic follow-up were conducted 3, 6 and 12 months after procedure. At these sessions the following traits were observed: suitable clinical evolution, absence of symptomatology, radio-lucid area and suitable coloring of dental tissues.

**Key words:** Intra-coronary bleaching, thermo-catalytic technique, dyschromia.

**Palabras clave:** Blanqueamiento intracoronario, técnica termocatalítica, discromía.

#### RESUMEN

Paciente femenino de 20 años de edad, quien acudió al Servicio de Odontología del Hospital Militar Regional de Guadalajara, Jalisco, por cambio de color en sus dientes. A la exploración, se observó discromía en el incisivo central superior derecho, las pruebas de sensibilidad negativas, radiográficamente ausencia de zona radiolúcida, diagnosticándose necrosis pulpar, lo cual condujo al tratamiento de conductos en sesión única, para posteriormente realizar blanqueamiento intracoronario con técnica termocatalítica. Se llevó a cabo control clínico-radiográfico a uno, tres, seis y 12 meses, observándose en estos periodos una adecuada evolución clínica, ausencia de sintomatología, zona radiolúcida y coloración adecuada de los tejidos dentales.

#### INTRODUCTION

An endodontically treated tooth with intrinsic color alterations requires esthetic treatment in order to regain chromatic characteristics similar to those of neighboring teeth, especially in cases when the tooth is located in the upper anterior segment.<sup>1</sup> To be considered ideal, a dental whitening procedure must be effective, prompt, long-lasting and incurring in no risks of cervical resorption, in order to solve the dyschromia problem. In order to achieve success, knowledge of limitations and possible untoward effects related to treatment is essential.<sup>1</sup>

Sodium perborate is highly soluble in water and saliva and possesses high antiseptic power due to oxygen release. In powder form it is stable and when fresh, it contains about 95% perborate; this corresponds to 9.9% available oxygen when in presence of acid, lukewarm air or water, it decomposes to form sodium metaborate, H<sub>2</sub>O<sub>2</sub> and oxygen.<sup>1</sup>

In cases when an endodontic procedure involves intrinsic tooth whitening, the whitening agent spreads

from the chamber dentin within the enamel internal surface, and not contacting the enamel external surface, where the whitening effect is the result of the oxidation reaction in the pigmented dentin.<sup>1,2</sup>

The purpose of the present article was to consider intrinsic whitening as a rehabilitation alternative, as well as to provide characteristics, advantages and showing step-by-step, the thermo-catalytic technique of intra-coronary whitening using sodium perborate as active agent. This treatment clearly respects the biology of the tooth subjected to root canal treatment.

\* Endodontics Specialist, Head of the Dental Department, Regional Military Hospital, Guadalajara, Jalisco, Mexico.

§ Professor, Endodontics Graduate Program, School of Dentistry, Quetzalcoatl University, Irapuato, Guanajuato, Mexico.

<sup>||</sup> Dentistry Intern, Guerrero Autonomous University, attached to the Regional Military Hospital, Guadalajara, Jalisco, Mexico.

**CASE PRESENTATION**

A 20 year old female patient attended the Endodontics Service of the Medical Specialty Unit of the Regional Military Hospital, Guadalajara, Jalisco. The patient complained of a central incisor exhibiting a darker shade than the other teeth. Upon interrogation, the patient revealed history of epilepsy, onychofagia, and no history of trauma.

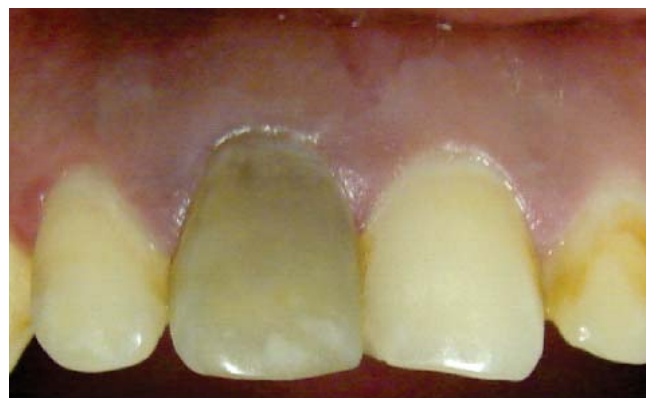Clinical examination revealed dyschromia in the right upper central incisor (*Figure 1*). Sensitivity tests revealed negative response to the procedure. Radiographic examination revealed absence of radio-lucid area and/or periapical alterations (*Figure 2*). Once clinical and radiographic data were gathered and integrated, a diagnosis of pulp necrosis + dyschromia was emitted. A root canal treatment procedure was achieved in one single session (*Figure 3*). At a second appointment intra-coronary whitening with thermo-catalytic technique was conducted.

The intra-coronary whitening procedure was conducted under total isolation with fitted rubber dam (Hygenic®). Neighboring teeth were exposed in order to compare their natural hue. Restorative materials were removed from the pulp cavity with a low-speed, number 3 round burr (SS White®). Remnants of filling materials and discolored dentin were withdrawn using Opmi 50 clinical microscope at 1X (Carl Zeiss).

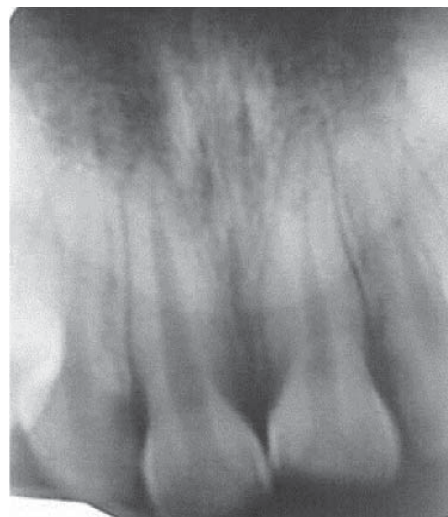Once the pulp cavity was free of organic and inorganic residues, it was irrigated with peroxide (Dermocleen 2.5-3.5%); excess was aspirated and a 2-3 mm space from the entrance of the root canal was freed with a number 4 Gates-Glidden burr (Maillefer). The cavity was then irrigated with bi-distilled water (kabipac 9%) and then dried. At that moment, the entrance to the canal was filled with glass ionomer cement (Vitremar®). This was achieved

with the purpose of creating a physical barrier to avoid micro-filtrations as well as internal resorption. Sodium perborate mixed with peroxide (Dermocleen 2.5-3.5%) was prepared until obtaining a thick consistency resembling «damp sand». It was then brought to the pulp chamber with a 33L spoon (SS White®); once the whitening agent was in place, the instrument was introduced at red hot heat, this allowed for oxygen release. This procedure was performed twice; upon completion, temporary cement was used to fill (Cavit 3M ESPE®). A slight improvement in the tooth's color was observed (*Figure 4*).

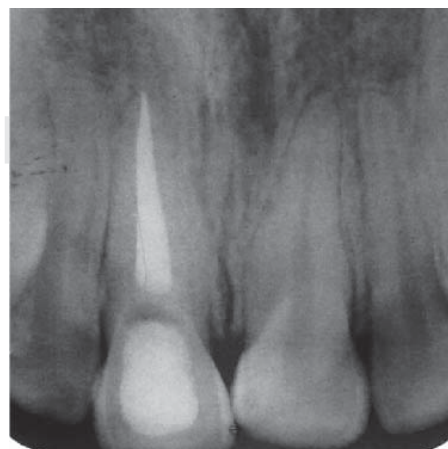
Thirty days after performing the whitening procedure, and after a clinical and radiographic assessment, it was determined to definitely fill the pulp cavity with a light-polymerizing composite material (Tetric N/Ceramic®). This was decided based on the suitable clinical circumstances and absence of



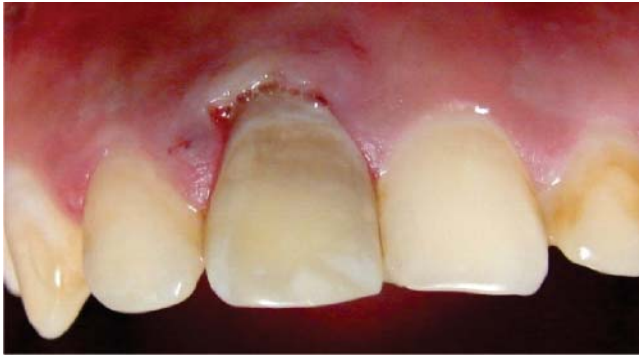**Figure 1.** Dyschromia of upper right central incisor.



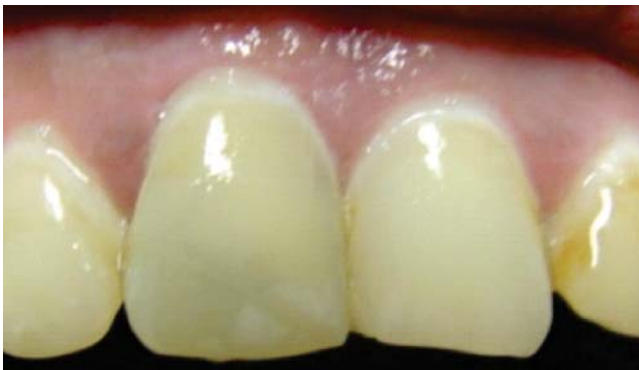**Figure 2.** Initial X-ray, no radio-lucid area can be observed.



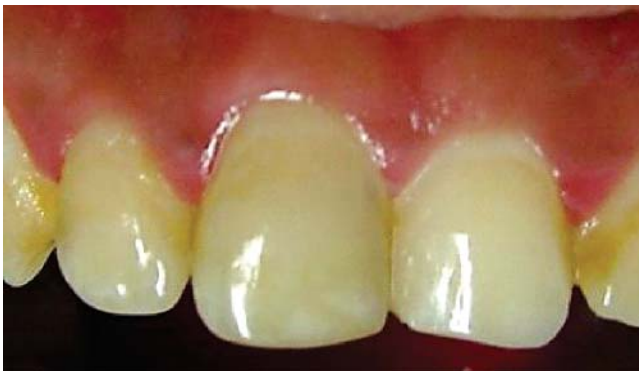**Figure 3.** Root canal treatment final X-ray.



**Figure 4.** Minimal dyschromia after whitening procedure.



**Figure 5.** Thirty days after procedure suitable hue can be observed.



**Figure 6.** Three month control visit, hue similar to neighboring teeth can be observed.

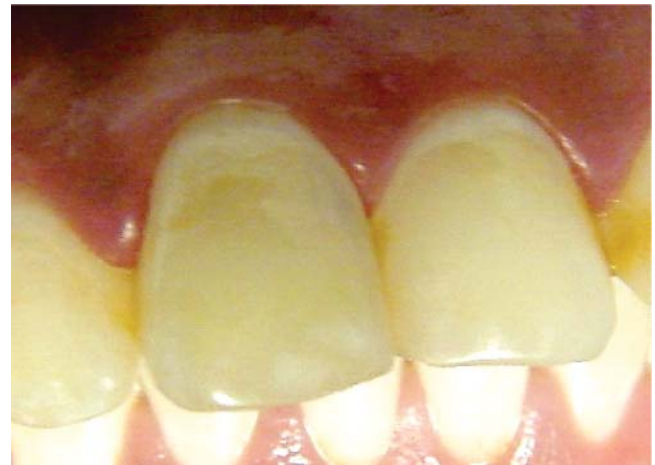pathological data, with no alterations in the color of the tooth (Figure 5).

Clinical and radiographic controls were conducted at 3, 6 and 12 months after the intracoronary tooth whitening procedure. Suitable evolution, absence of resorption and post-operative complications were

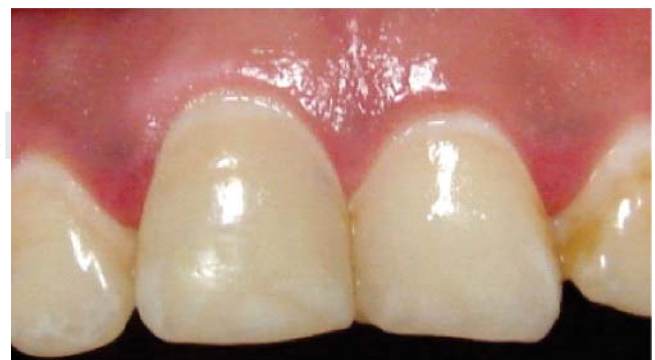observed (Figures 6, 7 and 8); therefore, this treatment alternative was deemed successful.

## DISCUSSION

Whitening agents can be made of hydrogen peroxide  $H_2O_2$  (common peroxide), carbamide peroxide ( $CH_4N_2O.H_2O_2$ ) or they can equally be made of sodium perborate<sup>2</sup> ( $NaBO_3$ ); in this last instance, sodium perborate can be associated to distilled water, physiological saline or hydrogen peroxide.<sup>3</sup> Hydrogen peroxide is a strong whitening agent, therefore, it must be used with great caution. One study states that internal whitening of non vital teeth using hydrogen peroxide at 30% concentration, either with or without sodium perborate, and equally with or without heat, can represent an efficient option to re-establish aesthetics in approximately 50% of treated cases.<sup>1</sup>



**Figure 7.** Six-month control visit. Absence of dyschromia is observed.



**Figure 8.** Twelve month control: suitable clinical circumstances can be observed.



Several studies have reported variations in the efficiency of whitening agents. Comparison was established between sodium perborate mixes with bi-distilled water or hydrogen peroxide. As a result, a mix of sodium perborate paste and water was introduced to be placed within the pulp chamber as whitening agent. Nevertheless, at a later point, hydrogen peroxide at 30 to 35% concentration was used to substitute water, in an attempt to achieve better whitening results.<sup>4</sup>

Although it was found that sodium perborate mixed with hydrogen peroxide at 3-30% was more efficient than when water was used, external root resorption has been reported at the neck of treated teeth after an internal whitening procedure.<sup>5</sup> For this reason, use of sodium perborate mixed with water instead of hydrogen peroxide has been recommended in order to prevent or minimize external root resorption. Nevertheless, whitening effect achieved with this latter mix can take more time to be efficient and produce clinically observed changes.<sup>6</sup>

Rotstein et al. (1993) and Weiger et al. (1994) reported significant differences in the effectiveness of sodium perborate mixed with either hydrogen peroxide in 3-30% concentrations or distilled water; stability of teeth treated with a mix of sodium perborate and water was as high as that obtained when mixing sodium perborate at 3-30% with hydrogen peroxide. Likewise, Ho & Goerig (1989) found that sodium perborate mixed with hydrogen peroxide at 30% was more effective than when mixed with water. Thermo-catalytic techniques use the heat source as a catalyst agent in the decomposition of the whitening agents in oxidizer products. They provide energy to the solution, enabling an easier diffusion on the tooth's surface. Simultaneously, temperature doubles the speed of reaction, achieving thus free oxygen activation; therefore, the whitening procedure is completed in shorter time.<sup>7-9</sup>

Possible complications notwithstanding, whitening procedures in non-vital teeth is a feasible option as esthetic treatment to restore color in a discolored tooth, as long as a suitable whitening agent is used and proper clinical protocol is adhered to. As a second alternative, the option would be to wear down the tooth in order to place a fixed prosthesis, crown or dental veneers.<sup>1</sup>

There are several techniques that can be used to achieve intra-coronary dental whitening, many offer great advantages. In the present case, sodium perborate enables the building of a cervical barrier which will prevent passage into the canal of the whitening agent towards the apical region and/or periodontal ligament. Thus lesser risk of the tooth's

external cervical resorption is encountered, since it avoids filtration of caustic substances through dentine tubules. If this were to be the case, a periodontal inflammatory response could be triggered which might elicit a resulting cervical root resorption.<sup>10</sup> Sodium perborate is a biocompatible whitening agent; hydrogen peroxide at 30% concentration is usually too aggressive, therefore, association of sodium perborate and distilled water has shown to be as effective as the association of sodium perborate and hydrogen peroxide.<sup>4</sup>

Another advantage of the thermo-catalytic technique is the fact that the heat source acts as a catalyst in the decomposition of the whitening agent into oxidizing materials providing thus energy to the whitening solution, and enabling expansive diffusion to the tooth's structure. Temperature doubles reaction speed and whitening process, achieving thus free activation of oxygen in contact with heat.<sup>5</sup> It is worth mentioning that thermo-catalytic whitening techniques are currently exhibiting effectiveness and success.<sup>6</sup> Color stability and whitening effect achieved with this technique are closely related to optimal conditions in etiology, pigmentation longevity, age, patient's habits and temporary restoration, which might prevent filtration of bacteria and pigmenting agents.<sup>7</sup>

Many pigmentations caused by dental materials show poor or no response to the whitening procedure. This is due to the fact that these materials contain inorganic substances which are impervious to the whitening agent since free radicals derived from peroxide act upon double carbonated links of organic substances. Therefore, metallic pigmentations (mercury, silver copper) caused by metallic posts, silver points, amalgam restorations, as well as pigmentations generated by sealing cements containing silver or iodine, are extremely difficult to alter or remove. This is even more so in cases when they have been in place for long periods of time. Nevertheless, the whitening technique can achieve a decrease in metallic salts, for example, from ferric state ( $\text{Fe}_2\text{O}_3$ ) to a less pigmented ferrous state ( $\text{FeO}$ ).<sup>1-3</sup> Therefore, it was considered that, in the present clinical case, trauma was the probable cause, even though the patient had reported absence of trauma; it is possible to assume that trauma might have taken place during an epileptic event (reported in patient interrogation), which might have triggered the tooth's pulp necrosis. This pigmentation was thus considered as easy to solve.

Cervical root resorption radiographic findings generally appeared up to six months after the

procedure was undertaken. This process can even end in the loss of the tooth. This complication is generally characterized by the fact of being asymptomatic, and can be detected only through routine X-rays.<sup>9</sup> Usually, lesions detected two years after procedure, are at an extremely advanced stage, and restoration of the tooth is deemed impossible. Early detection and restoration result in better prognosis.<sup>11</sup>

In some cases, initial resorption lesions can be arrested with the use of calcium hydroxide; nevertheless, more serious cases will require surgical procedures. It has been suggested to place the tooth in the calcium hydroxide chamber after completion of the whitening procedure so that the alkaline pH might neutralize the acid pH caused by the peroxide, in an attempt to prevent possible resorption.<sup>1</sup>

### CONCLUSIONS

MTA (mineral trioxide aggregate) is recommended, due to its action mechanism and high alkalinity. It is suggested to be used as a physical barrier to achieve whitening, it could also be supposed that due to its pH and alkalinity it would prevent resorption.<sup>10</sup> Nevertheless, further research is necessary to verify this hypothesis. Another fact to be considered is that with a MTA physical barrier in the pulp cavity, a 24 hour period should have to be observed, and undertake whitening procedures in a second appointment. This is due to the fact that MTA exhibits a prolonged setting time. It is equally important to consider that white MTA should be used and not the grey version, since if grey MTA were used, the presence of iron and manganese would cause greater dyschromia.<sup>3</sup> In the present case MTA was not used as a barrier, nevertheless, considering achieved results, it is possible to recommend intra-coronary whitening procedures as an alternative to prosthetic rehabilitation of endodontically

treated teeth, especially anterior teeth exhibiting 80% or more integrity of the clinical crown.

### REFERENCES

1. Oliveira M, Bittencourt JA, Salgado IO, Chaves F. Blanqueamiento dental en dientes no vitales: consideraciones actuales. *Int J Odontostomat.* 2008; 2: 61-6.
2. Ari H, Ungor M. *In vitro* comparison of different types of sodium perborate used for intracoronal bleaching of discoloured teeth. *Int Endod J.* 2002; 35: 433-6.
3. Ching HK, Palamara JEA, Messer HH. Effect of hydrogen peroxide and sodium perborate on biomechanical properties of human dentin. *J Endod.* 2002; 28: 62-7.
4. Celik EU, Turkun M, Yapar AGD. Oxygen release of tetra acetyl ethylene diamine (TAED) and sodium perborate combination. *Int Endod J.* 2008; 41: 571-6.
5. Attin T, Paque F, Ajam F, Lennon AM. Review of the current status of tooth whitening with the walking bleach technique. *Int Endod J.* 2003; 36: 313-29.
6. Weiger R, Kuhn A, Lost C. *In vitro* comparison of various types of sodium perborate used for intracoronal bleaching of discoloured teeth. *J Endod.* 1994; 20: 338-41.
7. Rotstein I, Mor C, Friedman S. Prognosis of intracoronal bleaching with sodium perborate preparations *in vitro*: 1-year study. *J Endod.* 1993; 19:10-2.
8. Ho S, Goerig AC. An *in vitro* comparison of different bleaching agents in the discolored tooth. *J Endod.* 1989; 15: 106-11.
9. Yui KCK, Rodríguez JR, Mancini MNG, Balducci, Goncalves SEP. *Ex vivo* evaluation of the effectiveness of bleaching agents on the shade alteration of blood-stained teeth. *Int Endod J.* 2008; 41: 485-92.
10. Rotstein I, Torek Y, Lewinstein I. Effect of bleaching time and temperature on the radicular penetration of hydrogen peroxide. *Dental Traumatol.* 1991; 7: 196-8.
11. Juárez NB. *Tratamento de perfurações radiculares em dentes de case com e sem cloreto de calico* [2004, Dissertação de mestrado]. Faculdade de Odontologia de Bauru, Universidade de São Paulo. Brasil.

Mailing address:

**CDMO Norberto Juárez Broon**

Servicio de Odontostomatología y Laboratorio Dental del Hospital Militar Regional y Unidad de Especialidades Médicas, de Guadalajara, Jalisco  
Calzada del Ejercito núm. 100, Col. General Real, 44450, Guadalajara, Jal.  
Teléfono: 33-3617-7310, ext. 185  
E-mail: endobr1@hotmail.com