



Gingival and bone tissue healing in lower third molar surgeries. Comparative study between use of platelet rich fibrin versus physiological healing

Cicatrización de tejido óseo y gingival en cirugías de terceros molares inferiores. Estudio comparativo entre el uso de fibrina rica en plaquetas versus cicatrización fisiológica

Galo Fernando Guzmán Castillo,* Mayra Elizabeth Paltas Miranda,* Juan Andrés Benenaula Bojorque,*
Katerine Isabel Núñez Barragán,* Denisse Vanessa Simbaña García*

ABSTRACT

Retained third molars are teeth linked to several conditions of the mouth, therefore, in most cases, surgical extraction is required. Surgical procedures undertaken to extract retained third molars bring about surgical procedures effects. The aim of the present study was to determine healing effectiveness in bone and gingival tissue with use of platelet rich fibrin in surgical procedures involving lower third molar extraction performed at the Surgical Center of the School of Dentistry, Central University of Ecuador in the period comprised May-September 2015. A comparative study was performed of 30 patients meeting inclusion criteria. Eight days after extraction, patients were controlled by means of direct observation of surgical site; 60 days after extraction, a digital panoramic X-ray of the jaws was taken and analyzed with software RadiAnt DICOM Viewer. For soft tissue, healing results were obtained with χ^2 test $p < 0.001$, and for bone tissue results were obtained with t-Student test $p = 0.015$.

Key words: Third molars, platelets, wound healing (scarring).

Palabras clave: Terceros molares, plaquetas, cicatrización de heridas.

Abbreviations, acronyms and units: PRF = Platelet rich fibrin, PRP = Platelet rich plasma, % = Percentage, mg = Milligrams, rpm = Revolution per minute, HU = Pixel value measure or Hounsfield units.

RESUMEN

Los terceros molares retenidos son dientes que se encuentran ligados a una serie de patologías en la cavidad bucal, por lo que se requiere su extracción quirúrgica en la mayoría de los casos. Los procedimientos quirúrgicos para extraer terceros molares retenidos, traen consigo efectos propios de la cirugía. El objetivo de este estudio fue determinar la efectividad cicatrizante en tejido óseo y gingival con el uso de la fibrina rica en plaquetas en la cirugía de terceros molares inferiores en el Centro Quirúrgico de la Facultad de Odontología de la Universidad Central del Ecuador en el periodo de mayo-septiembre del 2015, mediante un estudio comparativo realizado en 30 pacientes que cumplieron los criterios de inclusión. Se controló a los pacientes a los ocho días mediante observación directa de las heridas, y a los 60 días posteriores a la intervención quirúrgica una toma radiográfica panorámica digital de maxilares, analizada en el software RadiAnt DICOM Viewer. Los resultados obtenidos en cicatrización de tejido blando fueron mediante la prueba de χ^2 $p < 0.001$ y para tejido óseo mediante la prueba t de Student $p = 0.015$.

INTRODUCTION

Third molars are teeth most frequently found included. Lower first molars are most frequent, followed by upper first molars.¹ Third molar extraction is one of the most common procedures in dentistry.² Reasons for third molar extraction are varied, ranging from prophylactic measures to patients exhibiting large osteolytic lesions related to third molars.³

Extraction of impacted third molars causes surgery-related effects which represent great patient

* Ecuador Central University, School of Dentistry, Surgical Center.

Received: May 2016.

Accepted: November 2016.

© 2017 Universidad Nacional Autónoma de México, [Facultad de Odontología]. This is an open access article under the CC BY-NC-ND license (<http://creativecommons.org/licenses/by-nc-nd/4.0/>).

This article can be read in its full version in the following page:
<http://www.medigraphic.com/facultadodontologiaunam>

discomfort, such as pain after surgery, inflammation in the following 24 to 72 hours, trismus (lockjaw) suffered due to muscle contraction. «Extraction of third molars has an effect over the periodontal state of the lower second molar. Prevalence of periodontal disease in second molars is 77% before surgery, and 23% after surgical intervention». ⁴ Moreover, pain and post surgical inflammation are intimately linked to the type of surgical wound regeneration and healing (scarring). ²

Healing of a socket after extraction, in cases when no filling materials have been used is effected through second intention. ⁵ This healing takes place in three phases: first the inflammatory phase, followed by proliferative phase to end with remodeling. ⁶ Two types of healing are known in dentistry: healing by first intention and by second intention. First intention healing is achieved with use of sutures, second intention healing is effected with spontaneous closing of the surgical wound. ⁷

Tissue preparation of injured tissues in surgery to achieve healing is an important aspect of any surgical procedure, therefore, it is valuable for dental professionals to conduct this type of procedure and be knowledgeable in all aspects of normal tissue repair biology. ⁸

Platelet concentrates have been in use for many years to improve postsurgical circumstances in cases of impacted third molar extractions. These concentrates are obtained from human blood, and subjected to a centrifuging process following different techniques for their procurement.

Dohan et al, ⁹ in their study, report that platelet rich fibrin is a second generation platelet concentrate. Fibrin is a plasmatic fibrinogen active molecule ¹⁰ which together with platelets improves and accelerates tissue hemostasis and healing. ¹¹

Platelet rich fibrin is used to improve processes of bone and gingival tissue neo-formation. ¹² Bone tissue healing is dictated by intracellular and extracellular processes. Platelets play a fundamental role in wound healing, by forming blood clots and releasing growth factors. ¹³ Its use is based on accelerating healing processes of both soft and hard tissues. Due to its procurement technique, ¹⁴ it possesses certain advantages when compared to platelet rich plasma (PRP).

The present study is of a descriptive nature, where evaluation was made of healing in bone and gingival tissue either with or without use of platelet rich fibrin, used as autologous and adjuvant product for healing of wounds inflicted during lower impacted third molar surgery, to thus improve patients' recovery in a cost-effective manner without causing adverse reactions.

MATERIAL AND METHODS

Patient selection

For the present study, 30 female and male patients were selected, ages ranging 16-27 years, divided into three groups of 16-19, 20-23 and 24-27 years. Patients had undergone impacted lower third molar extraction surgery. The aforementioned age ranges were selected due to the fact that at this age patients attend more frequently the clinic for third molar extraction, because of the complications these impactions cause them. Extracted third molars were in the following positions: mesial angle, distal angle, horizontal, transversal and vertical. Type and class of position were not taken into account according to Pell & Gregory classification. Patients excluded from the study were those who exhibited alterations in platelet recount values, clotting times, hemorrhage time, prothrombin time, thromboplastin partial time, pregnant and nursing patients, patients with underlying systemic alterations, alcoholics, as well as drug and tobacco addicted patients. Patients were treated at the Surgical Center of the School of Dentistry, Central University, Ecuador. All patients were previously informed about the study and signed informed consent waivers.

Study design

Platelet rich fibrin meshes were placed in the socket corresponding to the extracted lower left third molar in order to compare it to the right lower third molar socket which had received no biological material or substance after extraction, the site had only received simple stitch suture points performed with vicryl 3-0 (Ethicon, Johnson and Johnson). Patients were prescribed amoxicillin + clavulanic acid, 875/125 every 12 hours and ketorolac, 10 mg every 8 hours, ingested by mouth. This medication was selected in order to avoid interaction in inflammation and healing processes. Inflammation was controlled with local means such as local ice and damp heat. Wounds were inspected after eight days; 60 days after surgery a digital panoramic radiograph was taken.

PRF procurement

Before surgical extraction, two 10 mL blood samples were harvested and placed in tubes (BD Vacutainer), to be both placed in a 3,000 rpm centrifuge appliance during 10 minutes ¹⁵ (centrifuge PLC series). No anti-clotting substance was added. The product of the

centrifuge process was taken to a tray in order to separate serum from fibrin during one minute. Finally, the fibrin platelet-rich mesh was placed in the socket after the extraction of lower left third molar (*Figure 1*).

Clinical and radiographic measurements

Eight days after surgery, wounds were inspected to ascertain whether they were still open or closing (*Figure 2*). A digital panoramic radiograph was taken 60 days after surgery. (I-max Touch 3d Owandy Radiology) to be then processed with software

RadiAnt DICOM Viewer, version 2.2.9.10728, with Ellipse tool. This is a medical-dental software which quantifies image contrast density with the mean of pixel value or Hounsfield units for computerized axial tomography images (*Figure 3*).¹⁶

Ethical considerations

Methodological, bioethical and legal bases of the present study were analyzed. Study was approved by the Ethics Subcommittee for Research in Human Beings of the Central University, Ecuador.

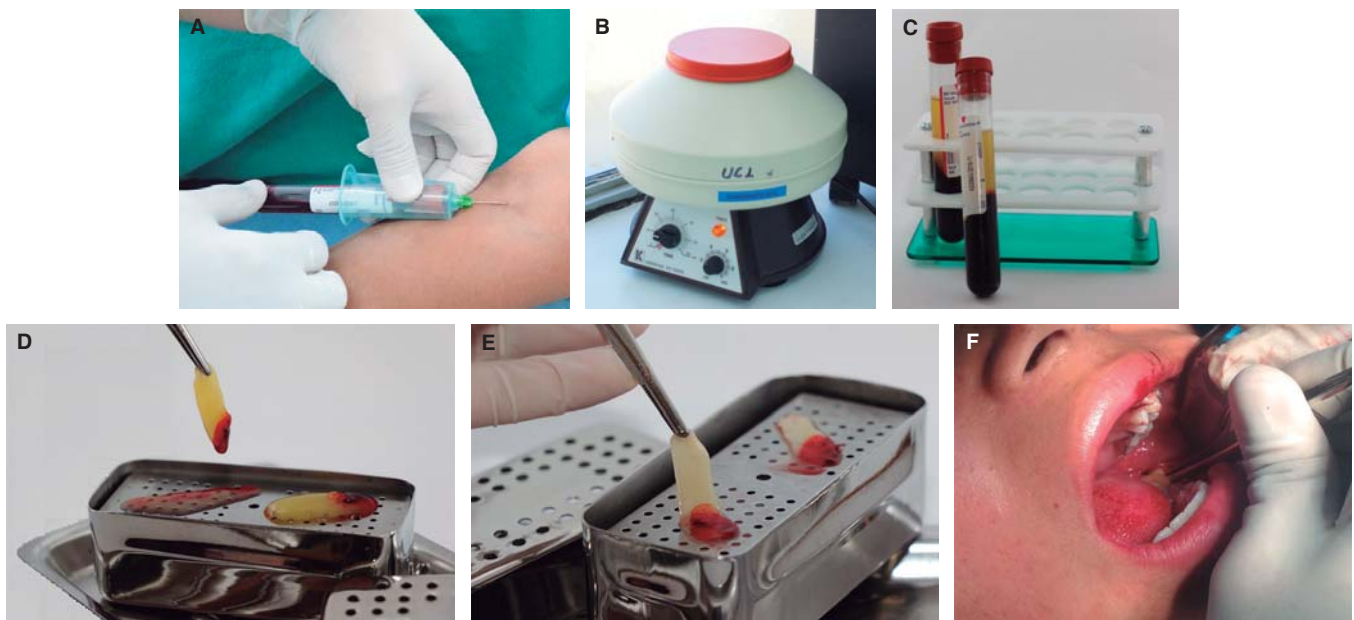


Figure 1. Process of PRF procurement and placement. **A)** Procurement of blood sample. **B)** Placement of tubes in centrifuge device. **C)** Centrifuged tubes after established time. **D)** Plasma filtering and fibrin modeling. **E)** Final result of platelet rich fibrin (PRF). **F)** Placement of PRF in the socket left lower molar socket.

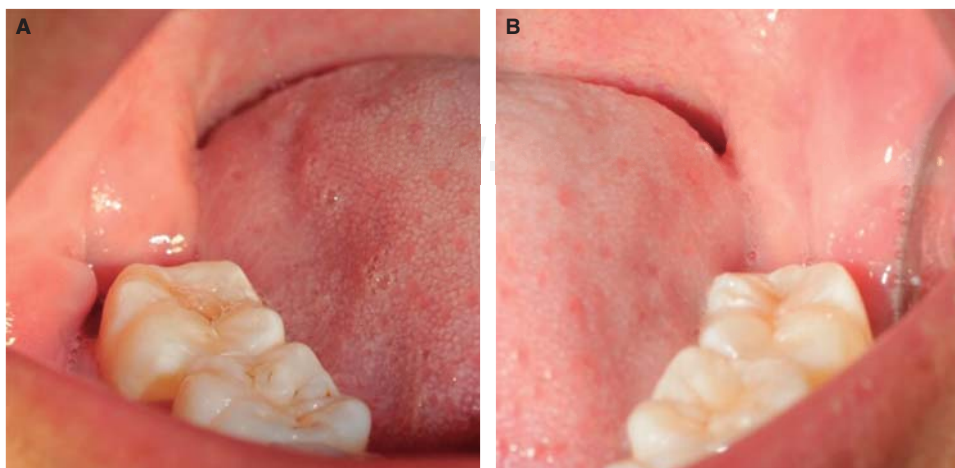


Figure 2.

Post surgical wound after 8 days. **A)** Open wound. **B)** Healed left wound.

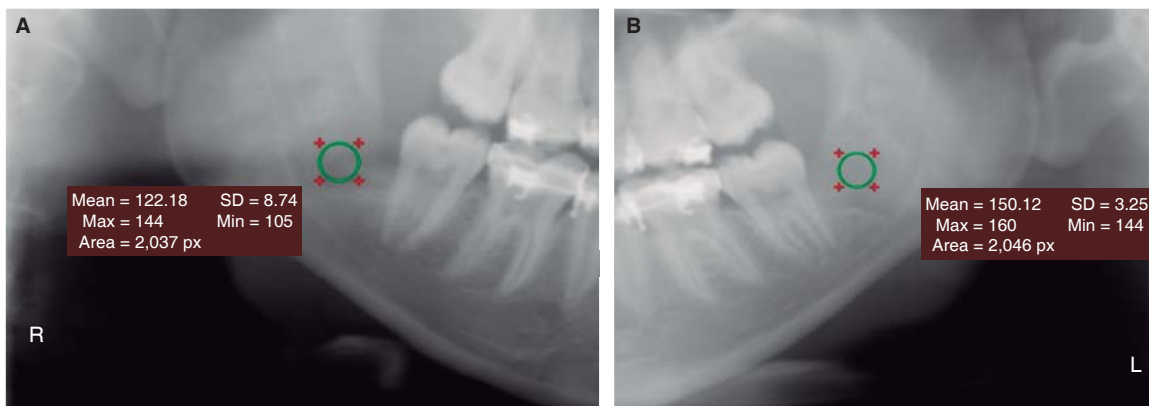


Figure 3. Results obtained with software Radiant DICOM Viewer. **A)** Radiographic density at right side. **B)** Radiographic density at left side.

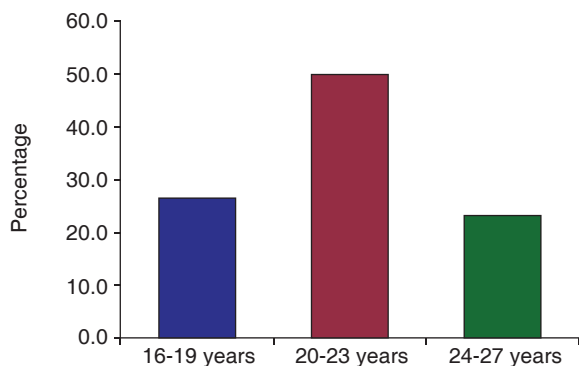


Figure 4. Percentage of cases according to patient's age.

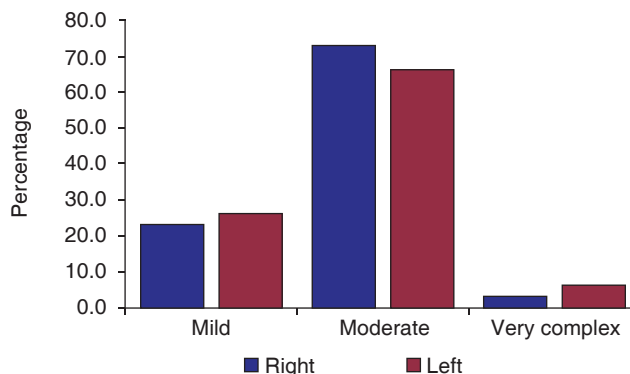


Figure 5. Percentage of cases according to extraction difficulty according to Pederson's scale.

Statistical analysis

The present study was conducted with Pearson χ^2 test for qualitative variables, which, in this case, was wound closure comparing both sides: where PRF was placed and the other side where PRF was not placed. T Student test was used for quantitative variables such as bone healing, which was quantified in software RadiAnt DICOM Viewer.

RESULTS

The present study included 30 patients, 15 males and 15 females. Patients were grouped according to age as follows: 8 patients ages 16-19 years, 15 patients aged 20-23 years and 7 patients aged 24-27 years (Figure 4). Pederson classification¹⁷ was used to establish extraction difficulty: as mild, moderate and very complex. Results were the following: 7 mild, 22 moderate and one very complex extractions in the right side, and 8 mild, 20 moderate and two very complex extractions in the left side (Figure 5).

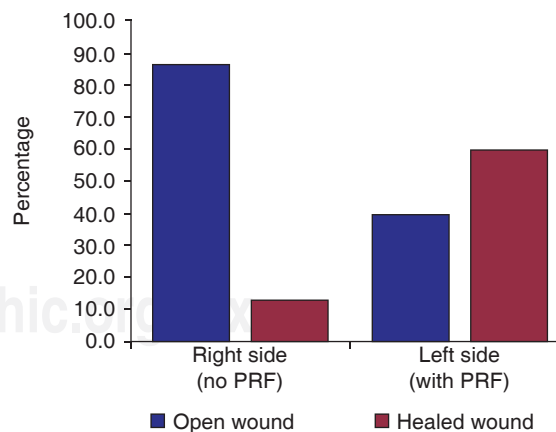


Figure 6. Soft tissue healing.

Gingival tissue healing in the surgical wound was as follows: open wound in 26 cases and closed wound in four cases in the control side; compared with 12 open wounds and 18 closed wounds in the left size, where

Table I. Soft and bone tissue healing with respect to age.

Age	Right side (no PRF)			Left side (with PRF)		
	Open wound (%)	Closed wound (%)	Bone tissue (density)	Open wound (%)	Closed wound (%)	Bone tissue (density)
16-19 years	87.5	12.5	154.29 HU	12.5	87.5	159.23 HU
20-23 years	86.7	13.3	161.75 HU	40.0	60.0	167.40 HU
24-27 years	85.7	14.3	159.80 HU	71.4	28.6	161.54 HU
Total	86.7	13.3	159.31 HU	40.0	60.0	163.86 HU

Shows results with respect to age. Results did not exhibit differences in soft and bone tissue healing either with or without PRF.

PRF had been placed, showing thus significance of $p < 0.001$ (Figure 6). No differences were observed with respect to gender $p = 1$ or age $p = 0.49$ (Table I).

Bone tissue healing obtained better punctuation on the experimental side, with density values of 163 HU when compared to the control side where 159.3 HU were encountered (Figure 7); t Student test provided results of $p = 0.015$. No differences were observed with respect to gender and age (Table I). According to Pederson's punctuation scale and criteria proposal, with respect to difficulty of extraction, best results were obtained for groups with mild extraction complexity (Figure 8).

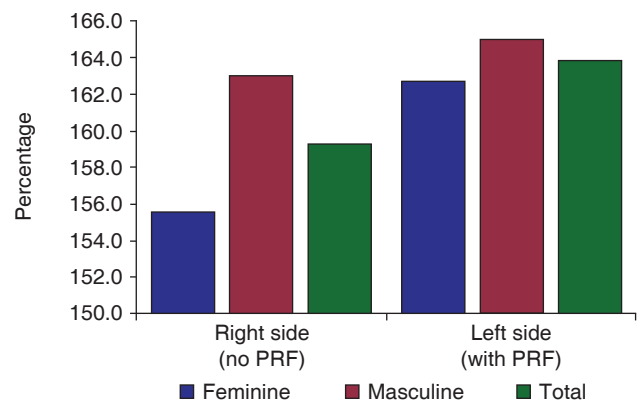
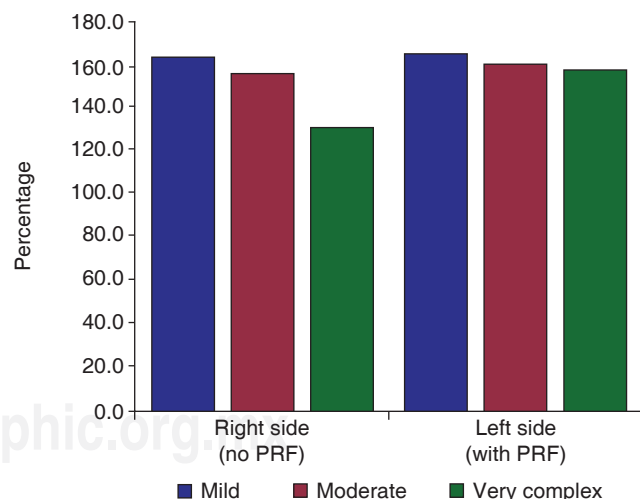
DISCUSSION

Improved and uncomplicated healing of wounds is highly desirable for patients after retained third molar extraction surgery processes. This fact has prompted research of related physicians and dentists in the area.¹⁸ Tissue repair processes take place due to growth factors found in platelet rich fibrin.¹⁹

So-called fibrin sealers are derived from human plasma; they replicate the final stages of blood clotting. These biocompatible and biodegradable compounds have been used for hemostasis and tissue healing.²⁰

The following were factors that might have influenced results of the present study: age, gender, surgery complexity, bacterial plaque control, patient's routine and feeding habits. Gender, age and surgery complexity were selected out of all the aforementioned factors due to their reliability and availability for data collection.

The present study included 30 healthy patients, male and female, distributed in an equal percentage (50%) for each group. Patients were divided according to age into groups of 16-19 years, 20-23 years and 24-27 years. In all patients, left side of the mouth was considered the experimental group and the right side was considered control group. The left side was

**Figure 7.** Bone tissue healing with respect to gender.**Figure 8.** Bone tissue healing according to extraction difficulty according to Pederson's scale.

considered experimental due to the fact of reduced visibility for surgery when compared to the right side which normally exhibits better field of vision for the surgeon as well as easier approach for surgery.

Results of the present study were assessed through direct observation for tissue healing, and through panoramic X-rays for bone tissue. These X-rays were analyzed with software Radiant DICOM Viewer in order to calculate imaging density of the socket after extraction.

PRF use in our study exhibited a result of $p < 0.001$, thus indicating based on statistical data obtained, that soft tissue healing is enhanced with use of this compound.

Analysis of soft tissue healing according to gender showed $p = 1$, it was thus concluded that wound closing was not dependent on patient's gender. When data were processed according to age, χ^2 test determined that in the experimental group age did not bear influence on soft tissue healing, showing a result of $p = 0.49$.

The present study concurred with similar studies conducted by Celio-Mariano et al,¹⁹ where platelet rich plasma, a PRF-like platelet concentrate, was placed. The study was performed on 15 volunteer patients, 7 male and 8 female, aged 18-22 years, where experimental group exhibited greater radiographic bone density after one, two and three months, $p < 0.05$.

In contrast to results obtained in the Kumar et al study²¹ conducted in 31 patients with average age of 26.1 years, the experimental group which received PRF in the socket after lower third molar extraction was composed of 16 patients; bone density assessed three months after third molar surgery exhibited a value of $p = 0.083$. Our study showed p values of $p < 0.015$ observed sixty days after third molar extraction surgery, interpreting thus this value as statistical data indicating that use of PRF bears influence on bone healing of control group.

Differences found among these results can be influenced by the manner in which bone density was evaluated, we used digital assessment in our study, whereas Kumar et al²¹ conducted analog evaluation by means of parameters studying directly panoramic X-rays.

In the Gürbützer et al study²² PRF application was assessed by means of bone gammagraphy four weeks after surgery, nevertheless no detectable results were observed in this examination. This difference with the results of other studies could be due to PRF preparation technique used, with a centrifuge device at 2,030 rpm during 10 minutes, as mentioned by Kumar et al.²¹

Obtained data on bone tissue healing were distributed according to age and gender similarly to soft tissue data. In the first group male gender exhibited

better mean values, both with and without PRF. These values were 163.0 and 165.0 HU respectively; female gender group exhibited mean values of 155.6 HU without PRF use and 162.7 HU with PRF use.

Results were similar in the study conducted by Celio-Meriano,¹⁹ both in control and experimental groups male gender exhibited higher mean values than female gender.

Age was distributed into three groups, comparatively, in bone tissue healing, best mean values were observed for age groups in the experimental group, when compared to the control group, group of patients 20-23 years old exhibited best values in all groups.

Finally, tooth extraction difficulty was calculated according to Pedersen scale.¹⁷ The experimental group exhibited best mean values, as well as the subgroup called mild complexity extraction, nevertheless it was observed that complexity of surgery did not exhibit statistical influence with bone healing.

Finally, with use of t-Student test, significant difference was observed in the mean value of imaging density of the socket after extraction in digital X-rays. Results were improved when using PRF, since $p = 0.015$.

CONCLUSION

The present study showed that soft and bone tissue healing improves with use of PRF, endorsing thus its effectiveness. When age groups were analyzed, the 20-23 years group exhibited better bone healing when compared to the 16-19 years group, which in turn exhibited better soft tissue healing. When comparing genders, males exhibited better healing than females. Finally, when analyzing third molar extraction difficulty, healing was not significantly influenced in all cases, either complex, of medium complexity or those cases where surgery became fast and easy.

REFERENCES

1. Aguado-Santos A, Arteagoitia-Calvo I, Baca-Pérez R, Bermudo-Añino L, Bullón-Fernández P, Conde-Fernández D et al. *Atlas de cirugía oral*. Bermudo-Añino L, editor. España: Instituto Láser de Salud Buco-Dental; 2001.
2. Fierro-Serna VM, Martínez-Rider R, Hidalgo-Hurtado JA, Toranzo-Fernández JM, Pozos-Guillén AJ. Colocación de plasma rico en factores de crecimiento postextracción de terceros molares inferiores: reporte de un caso. *Rev Odont Mex*. 2011; 15 (2): 109-114.
3. Laissle Casas del Valle G, Aparicio-Molares P, Uribe-Fenner F, Alcocer-Carvajal D. Comparación del postoperatorio de dos colgajos en cirugía de terceros molares inferiores. *Rev Esp Cirug Oral y Maxilofac*. 2009; 31 (3): 185-192.
4. Duarte I, Tovar-Mattar R. Uso de fibrina rica en plaquetas para prevenir defectos óseos a nivel distal de los segundos

- molares inferiores erupcionados, posterior a la extracción de los terceros molares inferiores retenidos. *Rev Venez Cir Buco-Maxilofac*. 2013; 3 (1): 10-16.
5. Moreno MG, Espinal GJ, Tirado MM, Vélez O. AL. Hidroaxapatita reabsorbible y sulfato de calcio, en cavidades alveolares de terceros molares mandibulares impactados. *CES Odontología*. 1997; 10 (2).
 6. Chiapasco M. *Tácticas y técnicas en cirugía oral*. Milano: AMOLCA; 2010.
 7. Gallego A, Hincapié A, Tobaría J. Comparación en la cicatrización de tejidos blandos por cierre primario y cierre secundario en exodoncia de terceros molares incluidos del maxilar superior en la Clínica Integral del Adulto de la Universidad Antonio Nariño. Séptimo Encuentro Internacional de Semilleros de Investigación-EAM. Armenia, 2014 Mayo 21 y 22. pp. 284-287.
 8. Hupp JR, Ellis E, Tucker MR. *Cirugía oral y maxilofacial contemporánea*. Barcelona: Elsevier; 2014.
 9. Dohan DM, Choukroun J, Diss A, Dohan SL, Dohan AJ, Mouhyi J et al. Platelet-rich fibrin (PRF): a second-generation platelet concentrate. Part II: platelet-related biologic features. *Oral Surg Oral Med Oral Pathol Oral Radiol Endod*. 2006; 101 (3): e45-e50.
 10. Mosesson MW, Siebenlist KR, Meh DA. The structure and biological features of fibrinogen and fibrin. *Ann N Y Acad Sci*. 2001; 936: 11-30.
 11. Gassling V, Açil Y, Springer I, Hubert N, Wiltfang J. Platelet-rich plasma and platelet-rich fibrin in human cell culture. *Oral Surg Oral Med Oral Pathol Oral Radiol Endod*. 2009; 108: 48-55.
 12. Moreno-Reyes L, Marín-González G, Enríquez-Habib F, González-Gómez J, Moreno-Villalaz L, Cisneros-Sotelo L et al. Utilización de plasma rico en plaquetas para regeneración periodontal en un perro. *Rev Odont Mex*. 2004; 8 (3): 64-69.
 13. Wu CL, Lee SS, Tsai CH, Lu KH, Zhao JH, Chang YC. Platelet-rich fibrin increases cell attachment, proliferation and collagen-related protein expression of human osteoblasts. *Aust Dent J*. 2012; 57 (2): 207-212.
 14. Toffler M, Toscano N, Holtzclaw D, Corso M, Ehrenfest DD. Introducing Choukroun's platelet rich fibrin (PRF) to the reconstructive surgery milieu. *J Implant Adv Clin Dent*. 2009; 1 (6): 21-32.
 15. Kobayashi M, Kawase T, Horimizu M, Okuda K, Wolff LF, Yoshie H. A proposed protocol for the standardized preparation of PRF membranes for clinical use. *Biologicals*. 2012; 40 (5): 323-329.
 16. Frankiewicz M. *RadiAnt DICOM VIEWER* [Online]. 2016 [cited 2015 September]. Available from: <http://www.radiantviewer.com/dicom-viewer-manual/>.
 17. Diniz-Freitas M, Lago-Méndez L, Gude-Sampedro F, Somoza-Martin JM, Gándara-Rey JM, García-García A. Pederson scale fails to predict how difficult it will be to extract lower third molars. *Br J Oral Maxillofac Surg*. 2007; 45 (1): 23-26.
 18. Ogundipe OK, Ugboko VI, Owotade FJ. Can autologous platelet-rich plasma gel enhance healing after surgical extraction of mandibular third molars? *J Oral Maxillofac Surg*. 2011; 69 (9): 2305-2310.
 19. Célio-Mariano R, de Melo WM, Carneiro-Avelino C. Comparative radiographic evaluation of alveolar bone healing associated with autologous platelet-rich plasma after impacted mandibular third molar surgery. *J Oral Maxillofac Surg*. 2012; 70 (1): 19-24.
 20. Soffer E, Ouhayoun JP, Anagnostou F. Fibrin sealants and platelet preparations in bone and periodontal healing. *Oral Surg Oral Med Oral Pathol Oral Radiol Endod*. 2003; 95 (5): 521-528.
 21. Kumar N, Prasad K, Ramanujam L, Dexith J, Chauhan A. Evaluation of treatment outcome after impacted mandibular third molar surgery with the use of autologous platelet-rich fibrin: a randomized controlled clinical study. *J Oral Maxillofac Surg*. 2015; 73 (6): 1042-1049.
 22. Gürbüz B, Pikköken L, Tunali M, Urhan M, Küçükodaci Z, Ercan F. Scintigraphic evaluation of osteoblastic activity in extraction sockets treated with platelet-rich fibrin. *J Oral Maxillofac Surg*. 2010; 68 (5): 980-989.

Mailing address:

Galo Fernando Guzmán Castillo
E-mail: galofernandogc@gmail.com