



## Soft tissues and bone healing response in impacted third molar osteotomies

### *Respuesta de cicatrización ósea y tejidos blandos en osteotomías de terceros molares incluidos*

Zoila Carbonell Muñoz,\* Antonio Díaz Caballero,<sup>§</sup> Edgar Espinosa Gómez,<sup>||</sup>  
Yelisa Ríos Gómez,<sup>¶</sup> Laura Torres Carrillo<sup>¶</sup>

#### ABSTRACT

**Objective:** To determine differences between bone healing and soft tissues in the lower jaw of patients subjected to impacted third molar extraction after using a high and low speed rotary devices. **Material and methods:** Crossed clinical assay-type intervention study. Under local anesthesia, forty tooth extractions were performed (right and left) from 20 healthy patients. Two groups were thus formed: in group 1 high speed hand-piece was used, in group 2, low speed hand-piece was employed. Index cards were used to record time devoted to each patient as well as preoperative and postoperative clinical data related to inflammation, pain, opening limitations, bone healing and periodontal changes in the adjacent teeth. **Results:** When comparing high and low speed hand-pieces, statistically significant differences were found between pain, surgical time and probing depth; it was observed that low speed hand-piece generated lesser aggression to soft tissues. **Conclusions:** Accurate use of low speed hand-pieces allows a decrease of surgical time thus providing the patients with more suitable postoperative evolution.

**Key words:** (Mesh Database), osteogenesis, pain, inflammation, third molars, osteotomy.

**Palabras clave:** (DeCS BIREME), osteogénesis, dolor, inflamación, terceros molares, osteotomía.

#### RESUMEN

**Objetivo:** Determinar las diferencias en la cicatrización ósea y tejidos blandos en el maxilar inferior de pacientes sometidos a exodoncia de terceros molares incluidos después de la utilización del instrumental rotatorio de alta y baja velocidad. **Material y métodos:** Estudio de intervención tipo ensayo clínico cruzado, se efectuaron 40 extracciones dentarias (derechas e izquierdas) en 20 pacientes sanos bajo anestesia local, para lo que se formaron dos grupos: en el grupo 1 se utilizó la pieza de alta velocidad y en el grupo 2 la pieza de baja velocidad; se registró en una ficha el tiempo empleado en cada paciente y los datos clínicos preoperatorios y postoperatorios con relación a la inflamación, dolor, limitación de la apertura, cicatrización ósea y cambios periodontales a nivel de órganos dentarios adyacentes. **Resultados:** Existen diferencias estadísticamente significativas entre dolor, tiempo quirúrgico y en la profundidad al sondaje entre la pieza de alta y baja velocidad siendo la pieza de baja la que genera menor agresión a los tejidos blandos. **Conclusiones:** El adecuado empleo de la pieza de baja velocidad permite una reducción del tiempo quirúrgico proporcionando una mejor evolución postoperatoria a los pacientes.

#### INTRODUCTION

Extraction of impacted third molars is a very common procedure in oral and maxillofacial surgery. Technique and instruments used to perform the procedure have changed with time, up to the use of low-speed rotary instruments which presently is the preferred technique since it allows for significant decrease of the operating event time and greater comfort for both patient and clinical operator.<sup>1</sup>

Among surgeons, there is controversy with respect the use of high speed hand-piece in oral surgery due to the fact that one of the most common complication with the use of this technique is subcutaneous emphysema, which, by itself, can exhibit benign and limited sequels, but can cause events that, when left untreated and

\* DDS, Specialist in Stomatology and Oral Surgery, Education Graduate, Professor, University of Cartagena.

§ DDS, PhD in Biomedical Sciences, Professor, University of Cartagena. Periodontics Specialist, Universidad Javeriana. Education Graduate, Universidad del Norte.

|| Specialist in Oral and Maxillofacial Surgery, del Bosque University. Graduate School Professor in Stomatology and Oral Surgery, University of Cartagena.

¶ Oral Surgery and Stomatology Residents, University of Cartagena.

Received: March 2016.

Accepted: August 2016.

© 2016 Universidad Nacional Autónoma de México, [Facultad de Odontología]. This is an open access article under the CC BY-NC-ND license (<http://creativecommons.org/licenses/by-nc-nd/4.0/>).

This article can be read in its full version in the following page:  
<http://www.medigraphic.com/facultadodontologiaunam>

suffering complications, can potentially threaten the patient's life if they evolve to pneumomediastinum, pneumoperitoneum, pneumopericardium and pneumothorax.<sup>2</sup> To this date, there are no reports in dental literature about risk of suffering the aforementioned or other type of complication when using low speed handpieces.<sup>2</sup> Up to now, there have been no scientific recordings revealing data on clinical and radiographic postoperative differences which can be identified as, among others, bone formation, pain, inflammation, oral opening limitations, and periodontal changes. With the aforementioned, the present study targeted the construction of scientific knowledge with alternatives to choose between use of low or high speed rotary instruments, which will embody the possibility of incurring in lesser post-surgical damage in soft tissues, and thus achieve greater speed of bone healing.

## MATERIAL AND METHODS

A clinical assay type intervention study was conducted: 40 surgical extractions of impacted (right and left) lower third molars were performed, to be selected they had to be class II depth B and C (Pell & Gregory). All clinical operators were standardized in surgical technique and clinical measurements recording, reaching thus a Kappa of 0.80. Dental prophylaxis was undertaken before clinical intervention. Clinical interventions were performed allowing a lapse of one month and a half between them. Surgery time was taken into account, the same incision was performed in all patients for osteotomies; high speed hand-piece was used in one half of the arch, and low speed hand-piece was used in the other half. A suture point was applied, and finally, patients were medicated with the same drug and were instructed with the same post-surgical recommendations. The following measures were taken:

- Pain and inflammation: calculations were undertaken before 24 hours, after 24, 48 and 72 hours, with an analog visual scale (AVS) and measurements proposed by Amin and Laskin.
- Oral opening: it was calculated before 24 hours, after 24 hours and after 7 and 21 days.
- Bone formation: 12 weeks, clarifying that bone loss was quantified after 72 hours by means of a volumetric X-ray.
- Probing depth and attachment level: was taken at 24 hours, 30 days and 12 weeks.

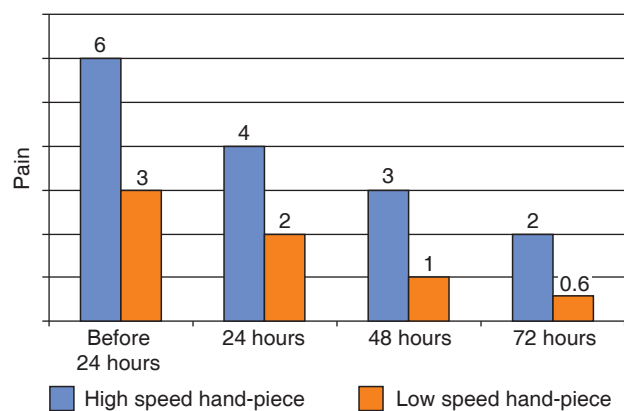
Statistical evaluation was conducted with SPSS version 21 statistical program. For data analysis, a descriptive statistic was conducted in function

of percentile distribution of all studied events: inflammation, pain, opening limitations, bone formation, probing depth and level of clinical attachment. Proportion difference and t student test were used to determine the existence of an association between presences of aforementioned different events with the use of both hand-pieces, a detailed data description was additionally undertaken.

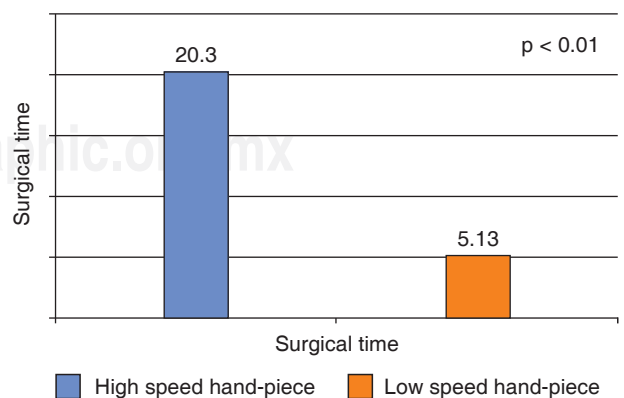
## RESULTS

When compared to patients operated on with low speed hand-piece, patients operated with high speed hand-piece required longer surgical time, and reported relatively more postoperative pain, lockjaw (trismus) and inflammation (*Figures 1 and 2*).

With respect to bone healing, patients operated with high speed hand-piece experimented greater bone healing than those operated with low speed hand-piece. With respect to probing depth, it was shown that



**Figure 1.** Measurement of pain intensity according to hand-piece used.



**Figure 2.** Measurement of surgical time used according to type of hand-piece used.

after three months, there were statistically significant differences between probing depth in second molars operated with high and low speed hand-pieces, patients operated with low speed hand-piece were favored (Figure 3).

**DISCUSSION**

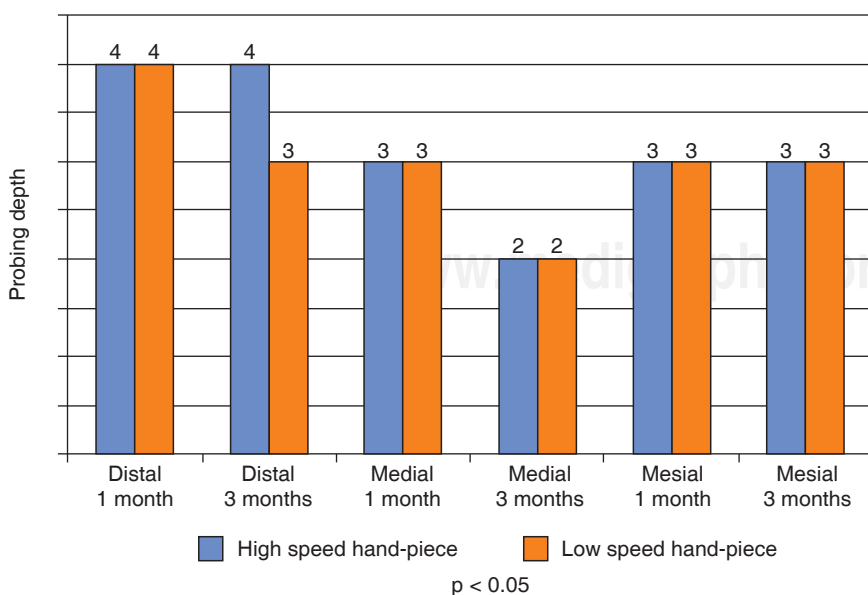
Age of participants ranged from 16-24 years, average age 19.2 years. Female was predominant gender with 75%. According to literature reports such as that of Casas del Valles Laissle<sup>3</sup> and Olate,<sup>4</sup> there is concordance with this percentage, which would lead us to think that females consult the dentist more frequently with respect to dental extraction procedures, the most common age when these procedures are performed is between 18 and 25 years.

With respect to pain, authors such as Amin and Laskin<sup>5</sup> did not find a relationship between pain and surgical time, nevertheless, in this study we did find meaningful data, in the sense that in procedures conducted with high speed hand-piece longer time was needed for the intervention and pain was moderate, differing with the mild pain elicited with low speed hand-piece. Nevertheless, authors such as Romero Ruiz Haug, et al<sup>6,7</sup> reached the conclusion that pain is more severe in the first 12 hours after surgical extraction of impacted lower third molars, in the present study we concur with it, since, in spite of having pain ranging from moderate to mild, the maximum pain peak was 6 (moderate) experienced in the 24 hours after completing the procedure.

With respect to inflammation, in the present study a substantial increase of all three measurements could be observed when using high speed hand-piece. Casas del Valle Laissle<sup>3</sup> proposed the theory that it could be considered that to greater surgical time, greater would be trauma caused to tissues, and therefore, more edema would be formed; this concurred with facts observed in the present study where it was found that when comparing it to low speed hand-piece, high speed hand-piece caused procedure lengthening, and thus more inflammation was caused, confirming thus the relationship between both variables.

With respect to oral opening decrease, Pedersen TK et al<sup>8</sup> asserted the existence of an intense relationship between pain and postoperative trismus (lockjaw) in cases of impacted third molar extraction, this research project concurs with it, this would then indicate that pain is an important cause of onset of trismus after this type of surgery, since patients operated on with high-speed hand-piece experienced greater pain and although this pain only ranged from moderate to mild, said patients suffered more oral opening limitations, differing from patients operated on with low speed hand-piece who always experienced mild pain and did not exhibit such marked trismus.

Bone formation is a time-consuming, complex process. It has been shown that most changes take place in the crown third of the socket, since that is the location of grater concentrations of Bundle Bone.<sup>9</sup> Clinical studies have documented an average of 4.0 to 4.5 mm horizontal bone resorption after an extraction



**Figure 3.**

Measurement of healing according to the rotary instrument used.

procedure.<sup>10</sup> In the present study, no significant differences were found between use of low speed and high speed hand-pieces, even though patients operated on with high speed hand-piece achieved more suitable bone formation.

Periodontal health of second molars does not only depend on appropriate surgical technique, it equally depends on post-surgical care and suitable oral hygiene in the oral cavity exercised by the patient. The first three months are considered cutting edge for periodontal healing. Young adults with impacted teeth could benefit from early extractions, since this would increase spontaneous periodontal healing.<sup>11,12</sup> Even though follow-up is not conducted after a year, which is the minimum time span employed by some research projects, it was found that after 3 months there were significant differences between probing depth in second molars operated on with high and low speed (at medium point) hand-pieces, which proved to be favorable to patients operated on with low speed rotary instruments.

### CONCLUSIONS

It can be concluded that pain, inflammation and opening limitations were the most frequent clinical events in patients treated with high speed hand-piece. Suitable use of low speed hand-piece allows for a decrease of surgical time, providing thus more favorable postoperative evolution in the patient. With respect to radiographic changes, it can be stated that high speed hand-piece was the instrument that most favored bone healing. Based on the aforementioned facts it can be established that low speed hand-pieces cause lesser postsurgical discomfort in procedures of impacted third molars extraction.

### REFERENCES

1. Monti LM, Lima de Castro A, Quirino-Louzada MJ, Pescinini-Salzedas LM. Estudio digital radiográfico y densitométrico en mandíbulas de cerdos sometidos a osteotomía con alta y baja velocidad, con refrigeración líquida. *Rev Esp Cir Oral Maxilofac*. 2010; 32 (3):102-107.
2. Vargas-Pérez V, Torres-Lagares D, Gutiérrez-Pérez JL. Enfisema como complicación en odontología. *Revista SECIB OnLine*. 2008; 3: 13-18.
3. Laissle Casas del Valle G, Aparicio-Molares P, Uribe-Fenner F, Alcocer-Carvajal D. Comparación del postoperatorio de dos colgajos en cirugía de terceros molares inferiores. *Rev Esp Cir Oral Maxilofac*. 2009; 31 (3): 185-192.
4. Olate S, Alister JP, Alveal R, Thomas D, Soto M, Mancilla P et al. Hallazgos clínicos y radiográficos de terceros molares con indicación de extracción. Resultados preliminares. *Int J Odontostomat*. 2007; 1 (1): 29-24.
5. Amin MM, Laskin DM. Prophylactic use of indomethacin for prevention of postsurgical complications after removal of impacted third molars. *Oral Surg Oral Med Oral Pathol*. 1983; 55 (5): 448-451.
6. Romero-Ruiz MM, Herrero-Climent M, Torres-Lagares D, Gutiérrez-Pérez JL. Protocolo de control del dolor y la inflamación postquirúrgica: Una aproximación racional. *RCOE [revista en la Internet]*. 2006; 11 (2): 205-215.
7. Haug RH, Perrott DH, Gonzalez ML, Talwar RM. The American Association of Oral and Maxillofacial Surgeons Age-Related Third Molar Study. *J Oral Maxillofac Surg*. 2005; 63 (8): 1106-1114.
8. Stoustrup P, Kristensen KD, Kùseler A, Gelineck J, Cattaneo PM, Pedersen TK et al. Reduced mandibular growth in experimental arthritis in the temporomandibular joint treated with intra-articular corticosteroid. *Eur J Orthod*. 2008; 30 (2): 111-119.
9. Jiménez D, Vives T, Bertos N, Pascual A. Tratamiento del alveolo postextracción. Revisión de la literatura actual a propósito de un caso clínico. *Revista Odontológica de Especialidades [Internet]*. 2011; 2-4. Disponible en: [http://www.infomed.es/rode/index.php?option=com\\_content&task=view&id=238&Itemid=28](http://www.infomed.es/rode/index.php?option=com_content&task=view&id=238&Itemid=28)
10. López J, Alarcón M, Sacsquispe S. Utilización de sulfato de calcio hemihidratado como material de relleno y barrera en un alveolo post-exodoncia: Una observación clínica, tomográfica e histológica comparativa a 4 meses antes de la colocación de implantes. *Rev Clin Periodoncia Implantol Rehabil Oral*. 2014; 7 (1): 29-31.
11. Inocéncio-Faria A, Gallas-Torreira M, López-Ratón M, Crespo-Vázquez E, Rodríguez-Núñez I, López-Castro G. Radiological infrabony defects after impacted mandibular third molar extractions in young adults. *J Oral Maxillofac Surg*. 2013; 71 (12): 2020-2028.
12. Montero J, Mazzaglia G. Effect of removing an impacted mandibular third molar on the periodontal status of the mandibular second molar. *J Oral Maxillofac Surg*. 2011; 69 (11): 2691-2697.

Mailing address:

**Zoila Carbonell Muñoz**

E-mail: [zbcarbonell@hotmail.com](mailto:zbcarbonell@hotmail.com)