



## Use of titanium mesh to rebuild «blow-out» fractures, clinical case report

### *Uso de malla de titanio para la reconstrucción de fracturas «blow-out», reporte de un caso clínico*

J Gerardo González Masso,\* Arturo Gómez Pedroso Balandrano §

#### ABSTRACT

Fractures located in the orbital floor, medial wall, lateral wall and orbital roof may occur isolated, combined, or in association to other facial fractures, this will depend on the level of energy transmitted during the process of the injury. «Blow-out» fractures of the orbit, are those fractures of the orbital wall in which the orbital rim remains intact.

The mechanism of these fractures is due to the sudden increase of intra-orbital pressure, such as trauma to the soft tissues of the orbit caused by a tennis ball or the blow of a human fist.

The aim of this article is to describe one orbital floor reconstruction technique conducted with the placement of a titanium mesh and post-operative evolution of a patient attending the regional hospital «Lic. Adolfo López Mateos» ISSSTE, Mexico City.

**Key words:** Orbital fracture, orbital floor, «blow-out» fracture.

**Palabras clave:** Fractura orbitaria, piso orbitario, fractura «blow-out».

#### RESUMEN

Las fracturas del piso orbital, pared medial, pared lateral y techo pueden ocurrir aisladas, en combinación o en asociación con otras fracturas faciales; esto dependerá del nivel de energía transmitido durante el proceso de la lesión. Las fracturas «blow-out» de la órbita son fracturas del piso orbital en donde el rim orbitario se mantiene intacto. El mecanismo de esta fractura es debido a un aumento repentino de la presión intraorbital como podrá ser el traumatismo recibido a los tejidos blandos de la órbita por una pelota de tenis o el golpe por un puño humano. El propósito de este artículo es el de describir una técnica de reconstrucción del piso de la órbita mediante la colocación de una malla de titanio en un paciente del Hospital Reg. «Lic. Adolfo López Mateos» ISSSTE, así como su evolución postoperatoria.

#### INTRODUCTION

The orbital skeleton is in a key location, this is due to its intimate relationship with the central nervous system, nose, nasal sinuses, and face. The orbit is also related to eye support and functioning.<sup>1</sup>

The orbit's primary function is to lodge and protect the ocular globe.<sup>1,2</sup>

The orbit is a pyramid-like structure. It contains four sides and is formed by seven bones (frontal, sphenoid, maxillary, lacrimal, ethmoid, zygomatic and palatine).

Orbital walls differ in thickness and strength. The orbital floor is the thinnest and least resistant wall; the lateral wall is the strongest and thickest.<sup>3</sup>

The roof is mainly made up of frontal bone, the sphenoid lesser wing presents minor contribution in the posterior region. It separates the orbit from the anterior cranial fossa. In elderly patients, there can be advanced degree of resorption, in which some regions surrounding the orbit are fused to the dura.<sup>4</sup>

The anterior portion of the roof is taken by an extension of the frontal sinus. The lacrimal gland fossa is also in that location. The trochlear fovea can be found in a medial position at the point where the superior oblique muscle is inserted. Bones that make up the orbital floor are the following: maxillary orbital process, a portion of the zygomatic bone and in a posterior position a portion of the palatine bone. The infra-orbital groove is formed at around 2.5 to 3 cm from the orbital rim. It becomes a canal containing infra-orbital nerve and vessels. It confers sensitivity

\* Former resident, Maxillofacial Surgery Service, Regional Hospital «Lic. Adolfo López Mateos», ISSSTE, Mexico City.

§ Head of Maxillofacial Surgery Service, Regional Hospital «Lic. Adolfo López Mateos», ISSSTE, Mexico City.

to the upper lip's soft tissues, to the mucosa of the anterior upper jaw, and to anterior teeth.

The floor separates the maxillary sinus from the orbital contents. The bone structure can be 0.5 mm in thick. This can provide easy access for tumors coming from the maxillary sinus, which can invade the orbit. The thinnest portion of the orbital floor is found in a medial location with respect to the infra-orbital canal. It is at this location where «blow-out» fractures take place, allowing the displacement of soft tissues towards the maxillary sinus.<sup>6,8,9</sup>

The lateral wall is made up by the wing of the sphenoid bone and the frontal process of the zygomatic bone. This is the strongest wall, but it can sustain fractures along its thinner portions, at the suture point where the greater wing meets the sphenoid and zygomatic bones. This wall separates the orbit from the temporal muscle.

The medial wall of the orbit is the most complex. It is formed by portions of the frontal, lacrimal, ethmoid and sphenoid bones. The maxillary portion contributes to shape the anterior portion, after it comes the ethmoid orbital lamina (lamina papyracea). This structure is extremely thin (0.2 to 0.4 mm) and makes up the longest portion of this wall. Ethmoidal sinus infections penetrate through this way into the orbit, causing orbital cellulite. The lacrimal crest is located at the most anterior portion. This crest is made up of the maxillary frontal process, in a posterior location the lacrimal fossa is found, partly made up by lacrimal bone. At approximately 20 to 25 mm behind the rim the anterior ethmoidal foramen is found, and the posterior ethmoidal foramen is found 12 mm beyond it. The anterior ethmoidal lamina contains the anterior ethmoidal artery and the ethmoidal branches of the nasociliary bone. The posterior ethmoidal foramen transmits the posterior ethmoidal artery, and inconsistently, the speno-ethmoidal nerve which is a branch of the nasociliary nerve.<sup>3,9</sup>

For study purposes, the contents of the orbit can be divided into: eyelids, lacrimal apparatus, and extraocular muscles.<sup>9</sup>

Eyelids are specialized structures which perform the function of interrupting light. They also dampen the cornea and distribute a tear-drop coating over it.

The eyelids constitute the anterior boundary of the orbit. The eyelid skin is attached to the eyelid orbicular muscle, innervated by the seventh cranial pair. Eyelids blood supply comes from branches of the ophthalmic artery which comes from the internal carotid artery. Sensory branches emerge from the ophthalmic division of the trigeminal nerve. Upper and lower eyelids are innervated by the supra-orbital

and infra-orbital nerves respectively. The motor nerve of the palpebral elevator muscle comes from the ocular-motor nerve and the orbicular ocular muscle is innervated by the facial nerve.

The orbit contains seven muscles, out of which six (4 straight and two oblique) insert into the ocular globe to control movements, and the seventh, (palpebral elevator) lifts the upper eyelid.<sup>9</sup>

All four straight muscles have their origin in the periosteum of the orbital apex (Zinn tendinous ring).

Rectus and upper oblique muscles measure 4 cm in length; the lower oblique muscle measures 3.5 cm. Rectus muscles insert in front of the sclera at around 5 to 7 mm behind the corneal limbo.

The upper rectus muscle passes above the superior oblique muscle insertion; it is innervated by the oculomotor nerve.

The medial rectus muscle is the longest, it runs through a medial direction and penetrates into the bulbar sheath, to then insert into the sclera, in a more anterior location when compared to rest of the other extra-ocular muscles. It is innervated by the ocular-motor nerve and its main function is the medial movement (adduction) of the eye.

The rectus lower muscle has its origin underneath the optical canal, it is located all along the orbital floor. This muscle can be inadvertently damaged when exploring the orbital floor. This muscle is innervated by a branch from the inferior (lower) division of the ocular-motor nerve.

The lateral rectus muscle emerges from the lateral portion of the Zinn tendinous ring (Zinn annulus) it makes contact with the lateral wall, and penetrates into the bulbar sheath, to then fixate to Whitnall tubercle, forming thus the lateral ligament. The lateral rectus muscle is innervated by the sixth cranial pair (abducens, external oculomotor).

The upper oblique muscle is longer; it is the thinnest of all orbital muscles. It also emerges from the Zinn tendinous ring and passes in front of and underneath the eyelid elevating muscle, it passes over the medial rectus muscle. It becomes tendinous before passing through the trochlea (U shaped cartilaginous ligament inserted to the frontal bone at 4 mm inside the rim and in medial position with respect to the supra-orbital prominence). This tendinous muscle passes below, laterally and behind the upper rectus muscle, to then proceed to the ocular globe. It is innervated by the fourth cranial pair (trochlear, pathetic). The upper oblique muscle has the main function of lowering the pupil of the eye.

The lower oblique muscle does not emerge from Zinn's tendinous ring, It emerges from the posterior

orbital floor, going to the orbital rim and passes laterally to the lacrimal canal. The muscle passes in a posterior lateral direction, above the lower rectus muscle, all along the orbital floor, until reaching the posterior lateral portion of the ocular globe, where it inserts below the lateral rectus muscle. It is innervated by the oculomotor nerve and its function is to elevate the pupil of the eye.

The lacrimal apparatus can be divided into secretory and drainage systems. Tears are secreted through the lacrimal gland through excretory canals which empty into the conjunctival sac in the eye's upper quadrant. The fluid runs through the cornea to the medial angle of the eye, and is drained through the lacrimal canal, where it finally reaches the lower meatus of the nose, through the naso-lacrimal duct.

### FRACTURES OF THE ORBITAL FLOOR

Smith and Reagan<sup>6,8,10</sup> were the first to use the term «blow-out» fracture when referring to fractures of the orbit floor. This type of fracture can occur in conjunction with a displacement of the orbital content towards the maxillary sinus. The orbital rim and other orbital walls, remain intact in the «pure» form of the lesion. In the «impure» variant of the lesion there is a concomitant rim fracture. Blow out fractures can also occur in the medial and lateral walls. 20% of medial wall fractures are concurrent with fractures of the floor of the orbit.

Converse and Smith<sup>2</sup> described the mechanism of blow out fractures. This mechanism is an increase of hydrostatic pressure induced by a direct trauma to the ocular globe. Others have suggested an impact against the orbital rim, which, by itself, is insufficient to fracture the rim and results in the perforation and fracture of the thin orbital floor.<sup>6</sup>

Frequency of orbital wall fractures varies from 4% to 70% in patients suffering circum-orbital trauma. Luhr believes that isolated orbital floor fractures represent 5% of all fractures of the facial middle third.<sup>4</sup>

### DIAGNOSIS

Diagnosis of an isolated blow out fracture is difficult to emit. Tessler mentions the fact that in some instances, these fractures are not identified until diplopia sets in, which can take place several weeks after the accident.<sup>8</sup>

Presence of a blow out fracture is suspected when there is paresthesia of the infra-orbital nerve due to its relationship to the floor of the orbit. Furthermore, from the onset, limited eye movements can be observed.<sup>6,9</sup>

Among orbital floor fracture characteristic signs and symptoms we can mention the following: circum-orbital edema or hematoma, infra-orbital nerve paresthesia, diplopia in the primary or peripheral field of vision, enophthalmus when the edema abates, orbital emphysema and ipsilateral epistaxis.

In Watters and Caldwell, X-rays show ipsilateral maxillary sinus occupancy depending on the extension of the lesion.

The most accurate diagnostic tool to assess a blow out fracture is a computer based sagittal tomography, with 2 mm thick sections. According to Hammer Shlag & al this will provide a 100% diagnosis accuracy.<sup>7</sup>

Once the diagnosis is emitted, surgical procedure should be undertaken as soon as possible. Dulley and Fells, in their 103 patient study, observed the fact that patients exposed to surgical reconstruction at least 6 months after the lesion took place, experimented 72% enophthalmus incidence when compared to the 20% frequency which occurred when patients were operated on during the 14 days after the trauma.<sup>2</sup>

### TREATMENT

Several materials have been used to reconstruct the floor of the orbit. They can be alloplastic, allogeneic and autologous materials. Alloplastic materials used have been silicon. Teflon (polytetrafluorethylene), methyl methacrylate, gelfilm and hydroxyapatite. Advantages of these techniques are the fact of circumventing a second surgery to obtain donor material from the patient as well as the fact that these materials experience no resorption. Among disadvantages we can count the fact that these materials become encapsulated into a fibrous coating, and can present infection and extrusion or displacement towards the maxillary sinus.<sup>4</sup>

Allogeneic materials have also been successfully used, among these we can count allogeneic dura and lyophilized bone.

Autologous grafts have been extensively used for being very compatible. Nevertheless, the use of these grafts implies a second surgical event. Most frequent donor sites are the anterior portion of the iliac crest, upper skull bone and auricular cartilage.<sup>6</sup>

Treatment of the orbital floor begins with an exploration to ascertain the extension of the lesion. Once the lesions limits are determined, a reduction of herniated orbital tissue is undertaken towards the maxillary sinus. This tissue is frequently circum-orbital fat. After re-positioning the circum-orbit, a new material must be interposed to reconstruct the defect

and avoid further herniation. Martínez and Villalobos, recommend the following according to the size of the fracture: In cases of great loss, exceeding 50%, the first option would be reconstruction with autologous bone provided by the upper skull; mono-cortical bone layers enable reparation of the defect and projection of the ocular globe.<sup>2</sup> When dealing with small defects, alloplastic materials can be used, to simply act as a barrier to avoid herniation towards the maxillary sinus. When no bone limits are found in the fracture and no points are found to fixate a graft, specially shaped titanium mesh can be used which can be fixated to the orbital rim, where their own inherent rigidity will support the orbital content, thus avoiding enophthalmus.

### SURGICAL APPROACH

There are many techniques to perform internal incision of the lower lid, so as to guarantee access to the rim and the floor of the orbit. The difference among these techniques lies in the level of incision over the eyelid skin surface.

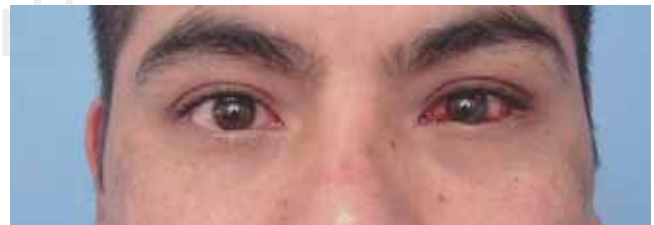The technique here described is the one deemed best since it exhibits esthetic benefits and sufficient scope to visualize the lower orbital rim and the orbital floor. This technique is called sub-ciliary, infra-ciliary or blepharoplasty incision. This technique was made popular by Converse in 1944.<sup>4</sup> A temporary tarsorrhaphy might be required to protect the ocular globe, to be withdrawn upon completion of the surgical event. Tarsorrhaphy implies the passage of a suture (black silk) though the tarsal region of both eyelids, thus causing their closure.

When conducting surgical approach, a horizontal incision is performed in a parallel position to the ciliary line, two millimeters underneath the eyelashes. A 1 to 1.5 cm lateral extension can be performed to totally expose the lower rim. Once the skin incision is made, dissection is performed between skin and orbicular muscle. Dissection is undertaken with scalpel or scissors. The tarsorrhaphy suture is used to retract the eyelid. Dissection is continued until reaching the rim level. At this point, with a scalpel, an incision of periosteum and muscle is performed, until reaching the bone of the orbital rim. The incision must circumvent the insertion of the orbital septum and must be performed around the orbital margin. The infra-orbital nerve is located at 5 to 7 mm below the rim and must be avoided when performing the periosteal incision. A sharp dissector must be used, using it through the length of the periosteal incision to separate borders surrounding the rim through the external and internal border. At this point, the orbital

floor is inspected. When performing the dissection, care must be taken not to cause further damage to the thin floor. With the support of another dissector, the trapped periorbital tissue at the fracture site is recovered. This tissue is generally found herniated towards the maxillary sinus. At this moment, the most adequate reconstruction material is selected. In the present article, titanium mesh was chosen due to the fact of it being resistant material that can be fixated to the orbital rim, avoiding any displacement. Once the reconstruction is completed, approach reparation is undertaken. Deep tissues will be repaired with 3 or 4 ceres resorbable suture, skin will be repaired with 4 ceres nylon sub-dermal suture.

### CLINICAL CASE

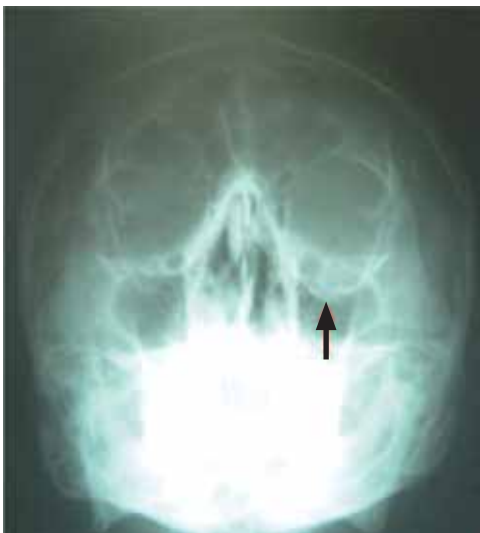A 37 year old male attended emergency services of the Regional Hospital «Adolfo Lopez Mateos» ISSSTE, showing trauma in the facial region caused by a fist blow sustained during a fight. The patient informed of no loss of consciousness, but informed dizziness when walking as well as double vision in lateral and upper movements. The patient exhibited edema and left bi-palpebral ecchymosis. Upon assessing eye movements, limited supra-adduction was observed, palpation did not reveal orbital rim fracture data (*Figure 1*). Radiographically, in the Watters type X-ray, a radio-opaque image was observed which indicated maxillary sinus involvement (occupation) (*Figure 2*). It was decided to repair the orbital floor under general anesthesia through a sub-ciliary (*Figure 3*) incision. A titanium mesh was placed and fixed to the rim with 4 mm mono-cortical screws (*Figure 4*). A week later, the patient's evolution was assessed. Remission on the limitation of eye movements was observed; two weeks later, complete remission was observed (*Figure 5*). The postoperative X-rays showed presence of osteosynthesis material in position, preserving orbital contents in their place (*Figure 6*).



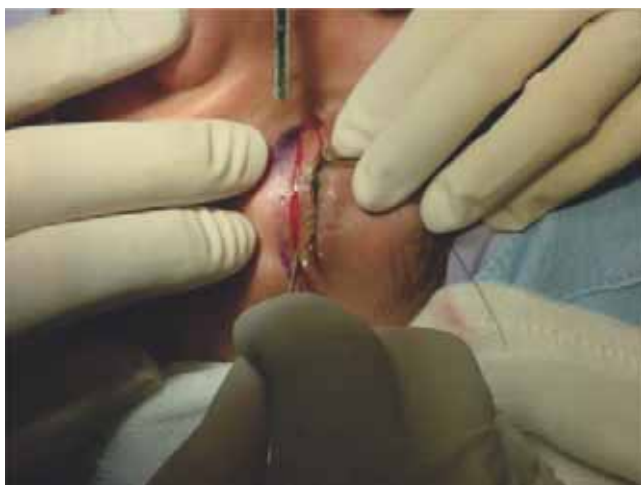**Figure 1.** Patient clinical picture. Edema and trans-conjunctival hemorrhage can be observed as result of trauma.

**CONCLUSION**

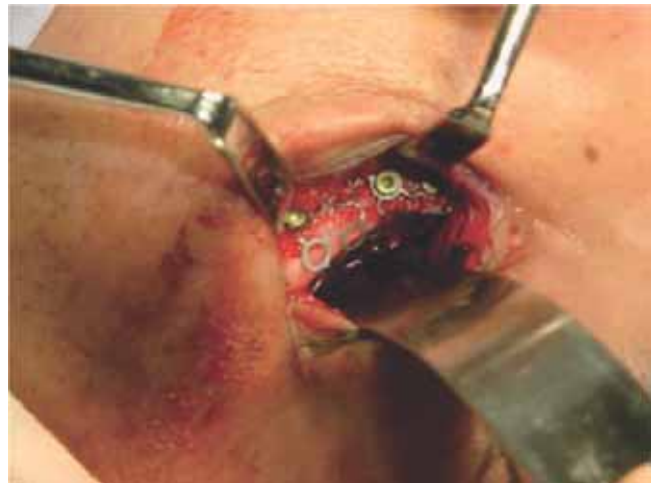Usage of Titanium mesh to fixate the orbital rim for reconstruction of orbital floor fractures represented an adequate treatment alternative, since it avoided creation of a second surgical site to obtain donor graft material. It also provided resistance as well as the certainty that the mesh would not suffer displacements since it was fixated to the orbital rim with mono-cortical screws. Displacement might occur when placing a non-fixated alloplastic graft (medpore, methacrylate).



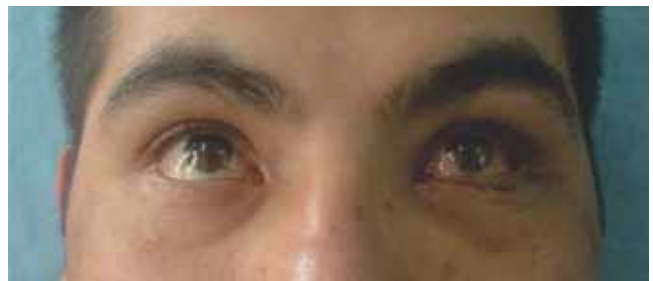**Figure 2.** Arrow points to the fracture site. Orbital contents herniation towards the maxillary sinus is observed.



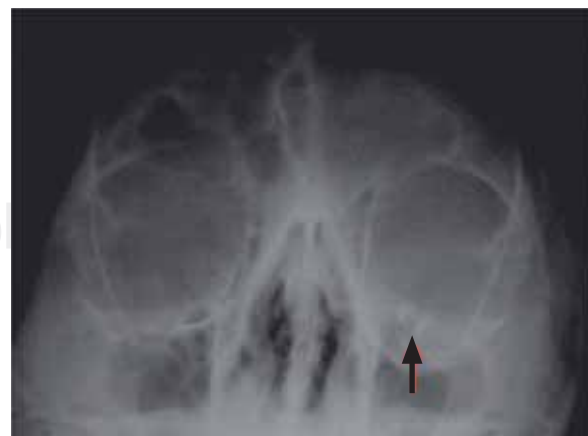
**Figure 3.** Design and incision of sub-ciliary approach described by Converse



**Figure 4.** Titanium mesh placement site and fixation to the orbital rim with mono-cortical screws.



**Figure 5.** Postoperative view two weeks after surgical procedure. Patient can perform unlimited eye movements.



**Figure 6.** Arrow points to the site where osteo-synthesis material is observed. Orbital contents are kept into proper position.

The patient's evolution was assessed after one week, after one month, and six months after the surgical treatment. Symptoms cleared 18 days after surgery. One week after surgery eye movements were clearly improved. During postsurgical period proper healing at the surgical approach site was observed, lacking the undesirable ectropion effects.

### REFERENCES

1. Schendel SA. Orbital trauma. *Oral and maxillofacial surgery clinics of North America*. W.B. Saunders Company, 1993: 5.
2. Martínez S, Villalobos C. Osteosíntesis cráneo-maxilofacial. Ergon España; 2002.
3. McCarthy JG. *Cirugía plástica: La cara I*. Editorial Médica Panamericana, Argentina; 1992.
4. Assael LA. Maxillofacial trauma, part II. *Oral and maxillofacial surgery clinics of North America*. W.B. Saunders Company 1999; 11 (2).
5. Ellis E. *Surgical approaches of the facial skeleton*. Williams & Wilkins USA; 1995.
6. Lloyd DE. *Anatomía oral*. Ediciones Doyma España; 1990.
7. Härtle F, Champy M, Terry HC. *Atlas of craniomaxillofacial osteosynthesis: microplates, miniplates and screws*. Thieme Germany; 1999.
8. Greenberg AM. *Craniomaxillofacial fractures: principles of internal fixation using the AO/ASIF technique*. Springer-Verlag USA; 1993.
9. Assael LA. Maxillofacial trauma, part I. *Oral and maxillofacial surgery clinics of North America*. W.B. Saunders Company 1998; 10 (4).
10. Tessier P et al. *Plastic Surgery of the orbit and eyelids*. Mosby Masson Publishing USA; 1977.

Mailing address:

**Arturo Gómez Pedroso Balandrano**

E-mail: argopebal@hotmail.com