



Radicular synostosis: Frequency study using panoramic x-rays as a diagnostic method

Sinostosis radicular: Estudio de frecuencia utilizando la radiografía panorámica como método de diagnóstico

Diego Vazquez,* Pedro Hetch,[§] Maria Elisa Martinez^{||}

ABSTRACT

Root synostosis is the term used to describe root fusion in a multi-rooted tooth, and which confers it with a single-rooted appearance. During tooth extraction procedures, an enclosed mandibular canal can be found between two roots and the nerve vascular bundle can result damaged. In endodontic procedures, it is more probable to find C-shaped canals, which will render treatment more exacting. These teeth used to suffer unfavorable diagnosis in periodontal treatments due to the disappearance of the inter-dental bone septum. The aim of the present study was to determine frequency of root synostosis cases in patients seeking treatment at the Radiology Service of the Buenos Aires School of Dentistry. Patients were remitted from other University services, as well as hospitals and welfare centers located in Buenos Aires. Patients arrived with written prescription for panoramic x rays. **Method:** The sample consisted of 1,000 patients, ages ranking 3 to 92 years. Panoramic x rays showed 797 synostosis cases. 64% of them were found in female patients and 36% in males. In the sample, 40.7% were of upper third molars, 19.9 right and 20.8% left, 29.6% were second upper molars, 14.8% right and 14.8% left. In lower third molars, the proportions were as follows: total: 17%, 8.9% right, 8.1 left, These were the teeth where greater amount of synostosis cases were found. Variable analysis showed a statistically significant difference among ages analyzed by decades of life, but no difference was found between gender of patients. In this study, we demonstrated the value of conventional routine panoramic images to detect root synostoses, as well as the possibility of performing more complex exams in order to ensure the proper and accurate diagnosis of this pathological entity.

Key words: Frequency study, radicular synostosis, panoramic x-rays.

Palabras clave: Sinostosis radicular, radiografía panorámica, estudio de frecuencia.

RESUMEN

En una extracción dentaria puede encontrarse el conducto dentario englobado entre las dos raíces y dañar el paquete vásculo-nervioso. En endodoncia es más factible encontrar conductos en forma de «C» que hacen más laborioso su tratamiento y en periodoncia suelen tener un diagnóstico desfavorable debido a la desaparición del septum óseo interdentario. **Objetivo:** Determinar la frecuencia de sinostosis radicular que caracterizan a la población que concurre a la Cátedra de Radiología de la Facultad de Odontología de la Universidad de Buenos Aires derivada de otras cátedras, hospitales y centros asistenciales pertenecientes a la Ciudad de Buenos Aires con prescripción escrita de radiografía panorámica. **Método:** Sobre una muestra de 1,000 pacientes de 3 a 92 años se observaron en las radiografías panorámicas 797 sinostosis, el 64% correspondieron al sexo femenino y el 36% al masculino. De las mismas, el 40.7% correspondieron a terceros molares superiores, 19.9% derechos y 20.8% izquierdos; 29.6% correspondieron a los segundos superiores, 14.8% derechos y 14.8% izquierdos; 17% a los terceros molares inferiores, 8.9% a los derechos y 8.1% a los izquierdos entre los dientes con mayor proporción de sinostosis halladas. El análisis de varianza demostró que hay diferencia significativa entre edades analizadas por décadas pero no se halló diferencias entre sexos. Se pudo demostrar el valor de la radiografía panorámica para evaluar este tipo de anomalía, como estudio radiográfico convencional de rutina y la posibilidad de poder solicitar un estudio de mayor complejidad frente al diagnóstico de la sinostosis radicular.

INTRODUCTION

Root synostosis is the name give to fusion of the roots of a multi-rooted tooth, giving it the appearance of a single rooted tooth. This type of anomaly is extremely frequent in molars, especially in upper third molars, conferring an appearance of a diminished number of roots in the mouth.¹

Root fusion can be the consequence of a coalition process lacking root cement apposition. It can

* Head of Practical Activities, Radiology Chair.

§ Head Professor, Biophysics Chair.

|| Head Professor, (Chairman), Radiology Chair.

School of Dentistry, Buenos Aires University, Buenos Aires, Argentina.

This article can be read in its full version in the following page:
<http://www.medigraphic.com/facultadodontologiaunam>

also be the result of underdevelopment of Hertwigs epithelial sheath.² Diagnosis of root synostosis is important when contemplating impacted (retained) lower third molar surgery, since the dental canal could, as a result, become enclosed within the roots. When extracting these roots, the vascular-nerve bundle found within the lower dental canal could result damaged.³ Teeth where root synostosis is present and which are periodontically compromised, rate an unfavorable prognosis due to the decrease in separation degree (separation angle) and root divergence (distance between two roots). Due to the disappearance of the inter-dental bone septum and the narrowness of its roots a diminished relation between crown and root is found. This substantiates as dental mobility in less advanced stages of periodontal disease. Due to the structure of these roots, resection techniques are contraindicated.³

In endodontic treatment, it is more common to find fused roots presenting «C» shaped canals. This type of anomaly is difficult to perceive in x-rays. Nevertheless, when performing preparation of the access cavity to the canals, and when the tooth is examined from the occlusal surface, the canal orifices cannot be differentiated, rather, a «C» shaped depression is observed in the floor of the chamber. This configuration indicates the existence of a continuous cleft among all canals, presenting curvature from the mesio-lingual plane up to the vestibular plane, and in distal-lingual direction, it can be observed around the vestibular plane.

These types of canals have great anastomosis diversity, as well as a large assortment of irregular communication nets which can interfere in the tridimensional obturation of root canals. In these cases, treatment results more arduous, compromising the success of endodontic therapy.³⁻⁸

Panoramic technique developments were initiated in Finland, in 1949 by Irjo Paastero. At a later point in time, several publications highlighted their use, since these techniques eased visualization and location of lesions. They also assisted in finding the so-called «radiographic findings» of asymptomatic lesions.

Panoramic x-rays are frequently used due to the simplicity of required technique and lack of discomfort for the patient. It is an inexpensive treatment for an initial evaluation and diagnostic formulation. It is of great significance due to its clinical implications, as well as for the evaluation of large populations.⁹⁻¹²

MATERIALS AND METHODS

Clinical files of patients attending the Radiology Service of the School of Dentistry from January 2005 until December 2007 were included into the electronic

filing system. 1,000 panoramic x-rays of patients, ages ranking 3-92 years were randomly selected. Root synostoses were grouped according to decade of life, gender of patient and location of the anomaly. Panoramic X rays were taken with a Cranex Thome (Finland) helical motion orthopantomographic appliance. Films used for this technique were 15cm x 30 cm Agfa Ortho CP-GU Brand (Argentina), as well as Kodak X-Omatic Cassette (USA) rigid framework with green light spectrum sensitive reinforcing screens.

Significance levels were determined through analysis of variance to assess frequency among genders and age groups. Acknowledged significance level was $p < 0.05$. In the present study, dental tissue structural alterations were not taken into consideration, since encountered shapes were difficult to visualize in panoramic x-rays due to the kinetic «flow».

Generalized shapes were recorded as well as those which allowed a diagnosis. Panoramic x-rays evaluators were assessed by the Dean of the Radiology Service of the School of Dentistry, University of Buenos Aires (kappa concordance index kappa = 88%).

ANOVA two-way tests were employed, instead of T-Student test. This was due to the fact that the former take advantage of all available information to analyze, in a single instance, the two variables under study (Gender-Age). This represented a statistically efficient practice and allowed the subsidiary measurement of the interaction effect of both studied factors.

RESULTS

Results showed that 64% (n = 571) cases corresponded to females and 36% (n = 429) to males. 797 synostoses were determined, out of which 64% (n = 507) appeared in females and 36% in males. The higher proportion of patients was found in the third decade of life, encountering 246 synostoses in this group, that is to say, 30.86% of the total sample.

Of detected root fusions, 40.7% (325) corresponded to upper third molars, 19.9% (n = 159) to right molars and 20.8% (n = 166) to left molars; 29.6% (n = 236) corresponded to second upper molars, 14.8% (n = 118) to right molars and 14.8% (n = 118) to left molars; 17% (n = 136) to lower third molars, 8.9% (n = 71) to right molars and 8.1% (n = 65) to left molars (Table I).

The quadrant system was observed: 35.5% (n = 283) synostoses in the first quadrant, 36.6% (n = 287) in the second quadrant, 13.92% (n = 111) in the third quadrant and 14.55% (n = 116) in the fourth quadrant.

Data were transformed into percentages of number of patients, this was due to the difference found between male gender (n = 290) and female gender

Table I. Lesion frequency absolute values according to affected teeth.

Tooth	Gender						Total	%
	N	F	%	N	M	%		
18	95		59.75	64		40.25	159	100
17	80		67.79	38		32.21	118	100
16	5		83.33	1		16.67	6	100
26	2		66.66	1		33.34	3	100
27	78		66.10	40		33.90	118	100
28	91		54.81	75		45.19	166	100
38	46		70.76	19		29.24	65	100
37	32		71.11	13		28.89	45	100
36	1		100.00	0		0.00	1	100
46	2		100.00	0		0.00	2	100
47	26		60.46	17		39.54	43	100
48	49		69.01	22		30.99	71	100
Total	507		63.61	290		36.39	797	100

Table II. Root synostoses frequency between genders according to age rank.

Age/Gender years	Female %	Male %	Total synostoses %
0 a 10	0	0	0.0
11 a 20	17	18	17.5
21 a 30	27	37	32.0
31 a 40	23	20	21.5
41 a 50	13	9	11.0
51 a 60	12	7	9.5
61 a 70	6	5	5.5
71 a 80	1	2	1.5
81 a 90	1	2	1.5
Over 91	0	0	0.0
total	100	100	100

(n = 507). Based on these results a two-way main effect ANOVA test was conducted, to compare lesion frequency among genders according to age ranks so as to measure a future Gender-Age interaction effect (Table II).

Analyzed results demonstrate significant differences among the number of root synostoses with respect to age of analyzed patients, and located by decades of life to the level of $p < 0.000024$ (Figure 1). They equally expose lack of difference among number of lesions between genders to the level $p = 0.05$ (Figure 2).

Otherwise, in the present study, no statistical interaction between Gender-Age variables was ascertained ($p=0.05$).

DISCUSSION

Panoramic x-rays bear the advantage of being able to study dental arches, neighboring zones, as well as all dental structures of the patient subject of study. Among disadvantages of these panoramic x-rays we can count lack of definition and isometric values in the image subject of diagnosis. The fact that the study area was much smaller needed to be borne in mind.⁹⁻¹¹

In the total 1,000 patient sample, after radiographic examination, a 29.9% of root synostoses were ascertained. In the present study we found a greater statistical difference than that found in consulted authors.⁵

The evaluation conducted in this study cannot be compared with respect to location of these anomalies according to gender and age group, since in studied bibliography, no analysis of this kind was found. Gender was not an influencing factor with respect to location of this anomaly. Nevertheless in the studied sample, a larger amount of female patients was encountered, but this did not affect percentages in the amount of lesions found in females over males. There were significant differences recorded with respect to age in the sample, since the group ranking from 21 up to 30 years of age showed significant increase in the amount of teeth with fused roots.

CONCLUSION

Root fusions found in patients attending Radiology Services at the School of Dentistry of the University of Buenos Aires during 2005-2007 were the most frequent anomalies among all development dental conditions observed in the present study.

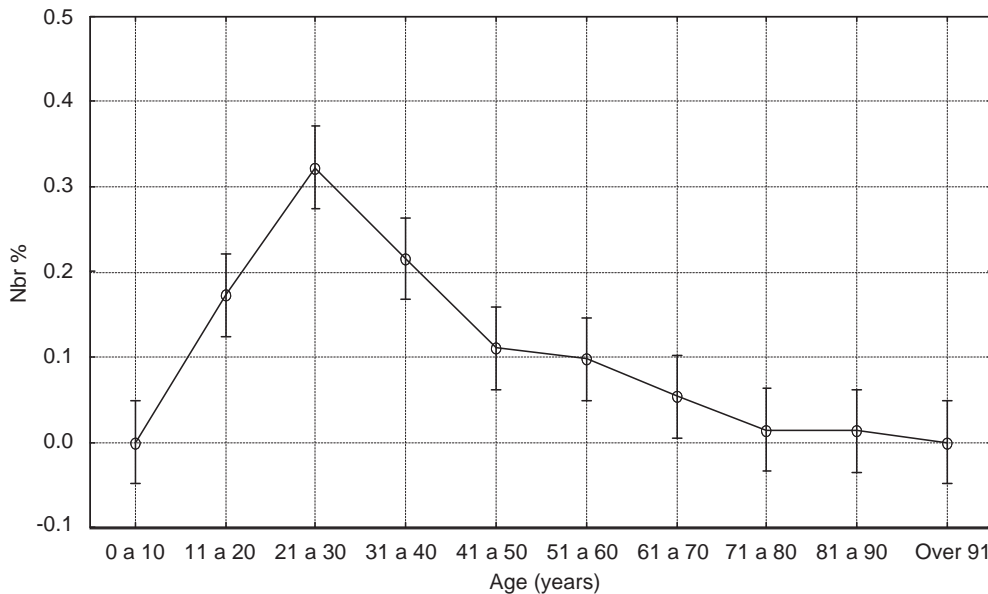


Figure 1: Frequency of root synostoses cases with respect to different age groups.

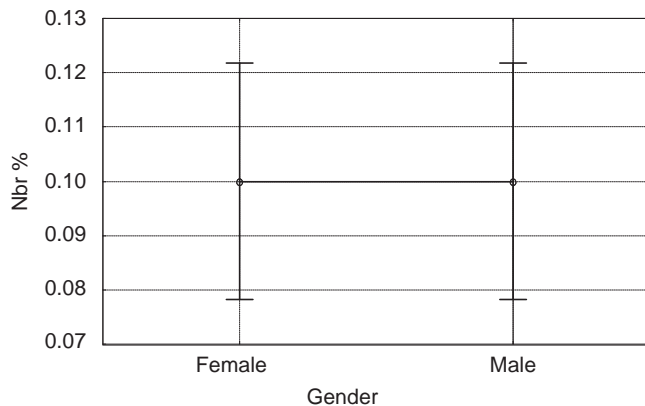


Figure 2: Anomaly cases according to the gender in the sample.

This study was able to demonstrate the worth of panoramic radiographs taken as a conventional radiographic study to assess this type of anomaly. This will then enable the clinician to request a more complex study when facing a diagnosis of root synostoses.

REFERENCES

1. Cabrini R. *Anatomía patológica bucal*. Editorial Mundi. 1988.
2. De Coster PJ, Mortier G, Marks LA, Martens LC. Cranial suture biology and dental development: genetic and clinical perspectives. *J Oral Pathol Med* 2007; 36 (8): 447-55.

3. Olivan-Rosas G, López-Jiménez J, Giménez-Prats MJ, Piqueras-Hernández M. Considerations and differences in the treatment of a fused tooth. *Med Oral* 2004; 9 (3): 224-8.
4. Cleghorn BM, Christie WH, Dong CC. Root and root canal morphology of the human permanent maxillary first molar: a literature review. *J Endod* 2006; 32 (9): 813-21.
5. Gallottini L, Barbato BRC, Migliau G. Endodontic treatment of a fused tooth. Report of a case. *Minerva Stomatol* 2007; 56 (11-12): 633-8.
6. Al-Fouzan KS. C-shaped root canals in mandibular second molars in a Saudi Arabian population. *International Endodontic Journal* 2002; 35 (6): 499-504.
7. Kremeier K, Pontius O, Klaiber B, Hülsmann M. Nonsurgical endodontic management of a double tooth: a case report. *Int Endod J* 2007; 40 (11): 908-15.
8. Min Y, Fan B, Cheung GS, Gutmann JL, Fan M. C-shaped canal system in mandibular second molars Part III: The morphology of the pulp chamber floor. *J Endod* 2006; 32 (12): 1155-9.
9. Ezoddini AF, Sheikhha MH, Ahmadi H. Prevalence of dental developmental anomalies: a radiographic study. *Community Dent Health* 2007; 24 (3): 140-4.
10. Rushton VE, Horner K. The use of panoramic radiology in dental practice. *J Dent* 1996; 24: 185-201.
11. Kawada S, Koyasu K, Zholnerovskaya EI, Oda S. Analysis of dental anomalies in the Siberian mole, *Talpa altaica* (Insectivora, Talpidae). *Arch Oral Biol* 2006; 51 (11): 1029-39.
12. Conte M, Lombardi P, Linfant J. A supernumerary tooth fused to the distal surface of a mandibular third molar. *J N J Dent Assoc* 2002 Winter-Spring; 73 (1-2): 8-9.

Mailing address:

Diego Vazquez
 Av. Corrientes 2362-2do piso, Depto «C» 1046,
 Ciudad Autónoma de Buenos Aires, Argentina
 Jv983@hotmail.com.ar