



## Basic criteria for finishing an orthodontic treatment

### *Crterios elementales para la finalizaci3n del tratamiento de ortodoncia*

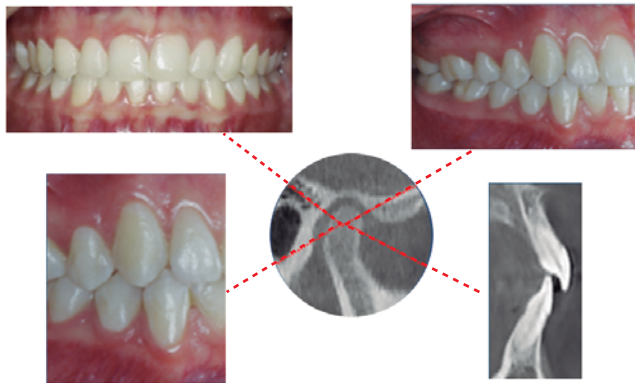
Lorenzo Puebla Ramos\*

The finishing stage of orthodontic treatment is perhaps the most complex and difficult to perform, because it means taking the decision to finishing properly in all areas that are required or simply end the treatment; in addition, on more than one occasion we are under a certain degree of stress due to various circumstances as it is the patient's desperation to see himself or herself free of appliances. It is precisely here where we have to ask ourselves whether our patient is in appropriate conditions for the completion of orthodontic treatment. We need to identify what are the criteria that must be met to make such an

important decision and in order to achieve a level of excellence as to the correct masticatory function, the precise functioning of the temporomandibular joint and its proper relation to the muscular-skeletal system, as well as a good respiratory function and finally an appropriate facial and dental aesthetics, which is usually the reason of consultation. To consider these criteria will provide post-treatment stability, avoiding any possible relapse or triggering some type of parafunction (*Figure 1*).

In the 20th century, researchers and authors of different techniques, philosophies and ways of thinking in the orthodontics were concerned to achieve a functional model that would finish the cases with the highest stability and aesthetics as possible, on the basis of a gnathologic and mutually protected occlusion. It was therefore taken as a requirement certain completion criteria, which were copied from research mainly from gnathology and dental occlusion schools, where those criteria would be of universal order.

In the last few years in clinical research efforts have been made to simplify and accelerate treatment, leaving aside or not paying due attention to the objectives to achieve an organic and stable occlusion; furthermore, the harmonious relationship that the soft tissues should have with the hard tissues at the time of obtaining anterior guidance with a mutually protected occlusion has not yet received the necessary attention. It is assumed that facial and dental aesthetics, as well as the patient's respiratory function needs, are



- Molar class I
- Maximum interdigtitation
- Condyles in CR
- 4 mm overbite
- 2-3 mm overjet
- 0.005 space for overjet
- Mesial-axial inclination of the canines
- Anterior guidance
- Canine guidance
- Mild curve of Spee

**Figure 1.** Ideal occlusion.

\* Board of Orthodontics and Maxillofacial Orthopedics of Mexico City Colegio de Ortodoncia y Ortopedia Dento Maxilofacial del Distrito Federal (COODDF).

© 2018 Universidad Nacional Aut3noma de M3xico, [Facultad de Odontolog3a]. This is an open access article under the CC BY-NC-ND license (<http://creativecommons.org/licenses/by-nc-nd/4.0/>).

covered at the time of achieving teeth alignment and a «good» occlusion.

Nowadays it seems that to meet these criteria of occlusion and function was not the purpose, but rather to end as soon as possible by means of the use of certain state-of-the-art techniques and tools. As if it was that «the one who ends faster is the best orthodontist». The emergence of new materials manufactured with cutting edge engineering and revolutionary techniques in the field of immediate biological response have been used to achieve this goal; the completion of cases as soon as possible. In addition, it is a model that is «selling» very well in seminars, training schools for post-graduate students and even in the doctor's office with the patients. Cases are displayed as trophies as if they were of the highest quality.

Orthodontic treatment is completed when it is due to finish; not before, not after and it is precisely this what the patient and, above all, us, must bear in mind at all times, without questioning the time that is required, nor much less the essential criteria for finishing.

It is necessary to perform a reflection or critical judgment, if the treatment has all the functional and

aesthetic features required to determine when is the right time to complete orthodontic treatment. Without doubt the topic generates questionings that we cannot ignore or overlook, and we should not only focus on finishing as soon as possible so that our patient recognizes us as modern orthodontists.

#### RECOMMENDED READINGS

1. McNeill C. *Fundamentos científicos y aplicaciones prácticas de la oclusión*. Francia: Ed. Quintessence; 2005.
2. Okeson JP. *Tratamiento de oclusión y afecciones temporomandibulares*. 7a ed. Ed. Elsevier; 2013.
3. Shklar G, Carranza FA. *Antecedentes históricos de la periodontología*. En: Carranza FA, Newman M, Takei H. *Periodontología clínica*. 9a ed. México: Editorial McGraw-Hill; 2014.
4. Lindhe J, Lang NP, Karring T. *Capítulo 30: Terapia oclusal*. En: *Periodontología clínica e implantología odontológica*. 4a ed. Madrid: Ed. Panamericana; 2005.
5. Alonso AA, Albertini JS, Bechelli AH. *Oclusión y diagnóstico en rehabilitación oral*. Buenos Aires: Ed. Panamericana; 2003.

Mailing address:

**Lorenzo Puebla Ramos**

E-mail: lorenzopr\_1@hotmail.com