



Technical description subapical osteotomy in the treatment of mandibular traumatic deformity

Descripción de técnica de osteotomía subapical en el tratamiento de deformidad mandibular postraumática

Luis Arturo Viteri Luzuriaga,* Diego Esteban Palacios Vivar,[§] Marcelo Cazar Almache,^{||} José Ernesto Miranda Villasana,[¶] Yonatan Josué Torres Cruz**

ABSTRACT

Post-trauma deformity after a complex trauma fracture or mishandle is not an often situation and represents a challenge for health professionals who treat the facial area. Treatment begins with a pre- and post-trauma radiographic interpretation, clinical assessment and measurement of study models. The aim of treatment is to recover function, aesthetics and correction of the facial sequel. The treatment plan for this condition may be orthodontic, surgical, rehabilitation or a combination of these. Several surgical techniques to correct maxillary deformities have been described. The most common osteotomies are at body, ramus and alveolar level. This article presents the case of a patient with right alveolar mandibular deformity as a consequence of an inadequate management of facial trauma re-treated with a subapical segmental osteotomy and cortical release to move the alveolar nerve.

Key words: Post-traumatic deformity, orthognathic surgery, subapical osteotomy.

Palabras clave: Deformidad postraumática, cirugía ortognática, osteotomía subapical.

RESUMEN

La deformidad facial posterior al trauma como secuela de una fractura compleja o una fractura mal manejada es una situación poco frecuente y representa un reto para los profesionales de la salud que tratan el área facial. Su tratamiento inicia con una interpretación de imágenes radiográficas previa y posterior al trauma, valoración clínica y medición de modelos de estudio. El objetivo del tratamiento está dirigido a recuperar la función, estética y en la corrección de la secuela facial. El plan de tratamiento puede ser ortodóntico, quirúrgico, rehabilitación o una combinación entre ellos. Se han descrito múltiples procedimientos para la corrección de la deformidad maxilar. Las técnicas más comunes son osteotomías a nivel de cuerpo, rama y procesos alveolares. Este artículo presenta el caso de un paciente con deformidad alveolar mandibular derecha como secuela de un manejo inadecuado del trauma facial tratado mediante osteotomía segmentaria subapical con liberación de la cortical para movilización del nervio dentario.

INTRODUCTION

Segmentary subapical osteotomy is a technique for orthognathic surgery used in cases of dentoskeletal malocclusions that cannot be dealt with only by conventional orthodontic treatment. Its use has been focused to achieve occlusal stability through dentoalveolar movement.^{1,2} Using this technique a favorable occlusal relationship may be established thus allowing good interaction between the dental arches at mastication during mandibular movements.³ These dental-alveolar changes are performed in an axial, antero-posterior, transverse and vertical direction with an alveolar-dental impact. Intrusion movements are useful when you need to mobilize more than 2 mm in adult patients.^{1,2,4}

Hullihen first described this technique in 1849.⁵ However, this surgery was limited only to the anterior

mandibular part. Hofer in 1942 and Kole in 1959 popularized the subapical technique for segments of both maxillaries in the anterior and posterior sectors.⁶ MacIntoch described the total mandibular alveolar osteotomy in 1974 for the correction of anterior open

* Maxillofacial Surgeon. Private practice – Ecuador.

§ Maxillofacial Surgeon, Monte Sinaí Hospital – Ecuador.

|| Head of the Postgraduate Center of the Faculty of Dentistry of the University of Cuenca, Ecuador.

¶ Master in Education, Chief of the Maxillofacial Surgery Service of the Regional Hospital «General Ignacio Zaragoza», ISSSTE, Mexico.

** Maxillofacial Surgeon. Private practice – Mexico.

© 2017 Universidad Nacional Autónoma de México, [Facultad de Odontología]. This is an open access article under the CC BY-NC-ND license (<http://creativecommons.org/licenses/by-nc-nd/4.0/>).

This article can be read in its full version in the following page:
<http://www.medigraphic.com/ortodoncia>

bite.⁷ Eliades and Hegdvedt reported in 1996 the first combination of sagittal osteotomy with complete subapical osteotomy for the successful correction of class II malocclusions.⁸ The biological bases of maxillary osteotomy were described by Obwegeser,⁹ Kole⁶ and Bell¹⁰ in their different articles. Kulbersh and Pangrazio compared total subapical osteotomy with bilateral sagittal osteotomy for the correction of class II dentofacial deformities showing for both techniques long-term stability.¹¹

CASE REPORT

A 22 year-old patient attended the Maxillofacial Surgery Service of the Monte Sinaí Hospital of the city of Cuenca with a history of facial trauma. Upon interrogation he declared to have suffered a traffic accident two years ago that caused him multiple bruises, mandibular fracture and loss of teeth. He was treated in a house of health by the emergency services where he was stabilized with plates and screws with a poor outcome.

Upon physical exploration he presented facial asymmetry, a discreet mandibular deviation to the right side, and a limited mouth opening (less than 30 millimeters). Intraorally, partial edentulism and bimaxillary protrusion were observed. The lower dental arch had a «V» shape with collapse on the right side towards the midline, a reduction in diameter of the anterior portion of the arch and absence of the lower incisors. The upper arch showed good arch form but also fracture of the central incisors. The dental-alveolar relationship was inadequate at the level of the right posterior segments (*Figures 1 and 2*). The upper segment created a deep bite with the lower

causing loss of dynamic and static function as well as aesthetics.

The therapeutic options to treat this sequel of facial trauma can be summarized in: distraction osteogenesis close to the midline, conventional orthognathic surgery, fracture again and perform segment mobilization or perform a segmental subapical osteotomy. Prior to the determination of a particular technique it was necessary to study the patient's photographs and models.

At the imaging study, the lateral headfilm was analyzed, as well as the posteroanterior and panoramic radiographs (*Figure 3*). In the first study, a proper relationship between the maxillae and the cranial base was found so conventional orthognathic surgery was discarded. The posteroanterior study showed an inadequate relationship between the teeth on the right side and a slight asymmetry. In the panoramic X-ray, the mandibular right side was measured as well as the diameter of the edentulous spaces and location of the mental canal. The distance from the apices and mandibular ridge was also measured. The canal may be in close contact with molars and the second premolar, then it distances itself as it progresses toward the midline. All the abovementioned measurements showed values necessary for any of the options proposed.

The models of both arches were mounted in an articulator. The distance from the cross bite was measured and model surgery was performed to assess the occlusal feasibility in the lateral movement of the right side of the lower model to simulate the subapical segmental surgery (*Figure 4*). When an acceptable occlusal stability of the right posterior segment and an appropriate canine relationship were verified, the subapical segmental osteotomy was determined as a viable treatment.

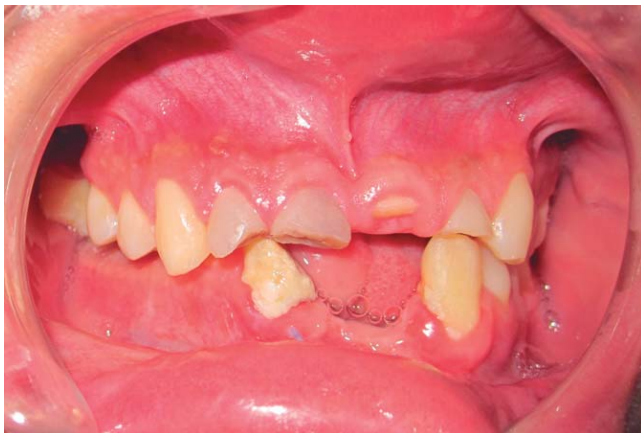

Figure 1. Lateral intraoral photograph. Fractured teeth, absence of the lower incisors. Right posterior scissor bite.

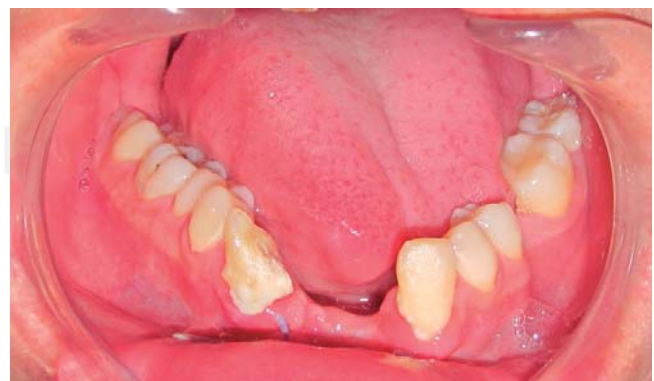

Figure 2. Lower intraoral photograph. «V»-shaped arch, right side intruded towards the midline.

Surgical technique

Under general anesthesia with nasotracheal intubation, two intermaxillary screws at the level of the alveolar side that was to be mobilized were placed; two more screws were placed on the upper arch between the premolar and the canine and the fifth screw was placed between the mandibular canine and premolar on the left side. The incision was circumvestibular on the mandibular right side; it was dissected from the last molar to the midline until the basal edge was reached while protecting the exit of the mental nerve and its three branches. After tracing the nervous path, the external cortex was removed to display and release the nerve thus protecting its exit with a Penrose (*Figure 4*). The subapical osteotomy was then performed following the tracing and respecting the 5 mm distance from the teeth. We delimited the posterior and anterior portions with a

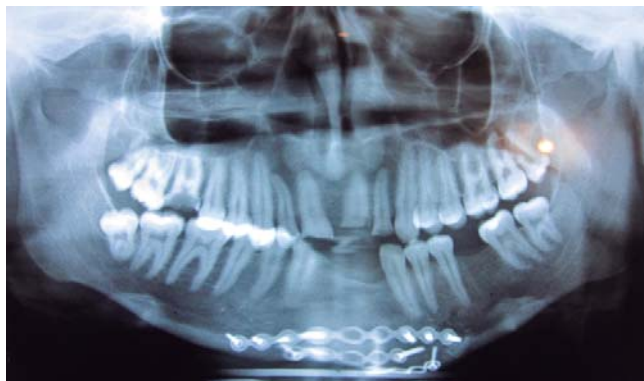


Figure 3. Initial panoramic radiograph. Screws and plates at the level of the mandibular marginal ridge.

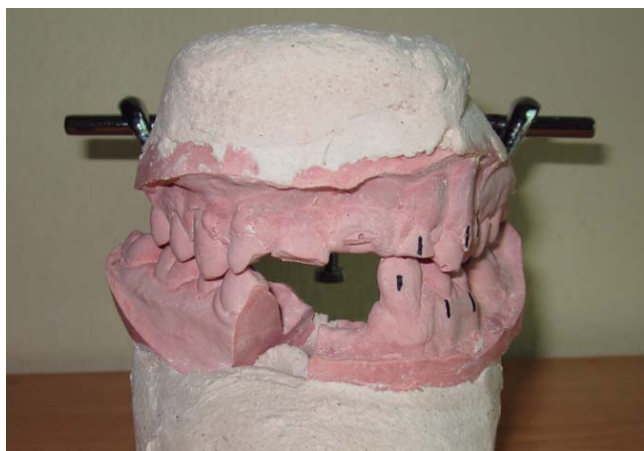

Figure 4. Model surgery.

vertical osteotomy; first, posterior to the molars and second, near the midline to move the whole alveolar segment in a block (*Figure 5*). Through wire traction in the intermaxillary screws the right alveolar and the left mandibular segments were moved in relation to the upper arch to reproduce the position planned in the model surgery and bring the segments to occlusion. We assessed the tension of the nerve to make sure that it was not affected by the new alveolar position and fixed the mobilized bony segments through osteosynthesis of 2.0 system and straight plates (*Figure 6*). At the level of the anterior defect created by the lateral and posterior mobilization lyophilized bone graft was placed. Hemostasis was verified and the mucosa was closed with continuous points of absorbable suture. The removal of the fractured teeth was not performed with the aim of preserving the bone for an immediate implant placement.

Control

Frequent controls were performed in which proper healing, good occlusal stability and preserved mandibular movements were observed (*Figure 7*). The patient referred a post-surgical paresthesia of the mental nerve, which disappeared after two months of treatment (*Figure 8*). An acrylic provisional was placed temporarily for aesthetics while waiting for the final prosthetic rehabilitation treatment. A control panoramic X-ray was obtained where the plates and screws appeared in a correct position (*Figures 9 to 11*).

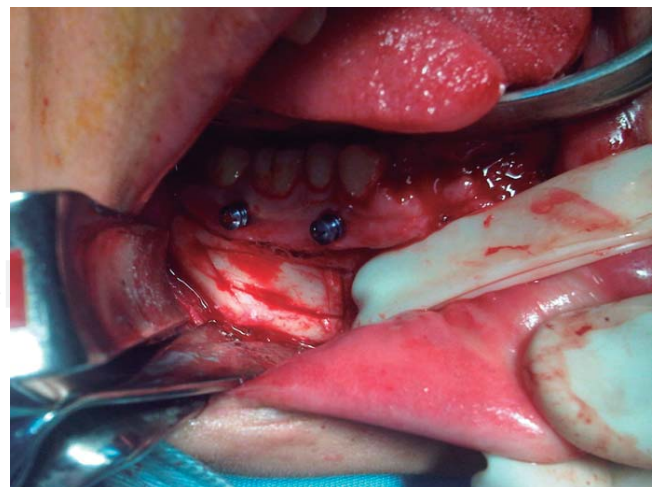


Figure 5. Surgery photograph. Intermaxillary screws in the right mandibular posterior segment, separation of the mental nerve with Penrose and corticotomy.

Due to the economic factor the patient requested to defer the final rehabilitation treatment. Three alternatives for the dental rehabilitation were discussed: osteointegrated implants, fixed prosthesis and removable prosthesis. The patient returned to his hometown, and continued with the final stage by choosing removable prosthesis as a temporary solution.

DISCUSSION

The sequelae of facial trauma are a group of complex diseases that pose a challenge for surgeons

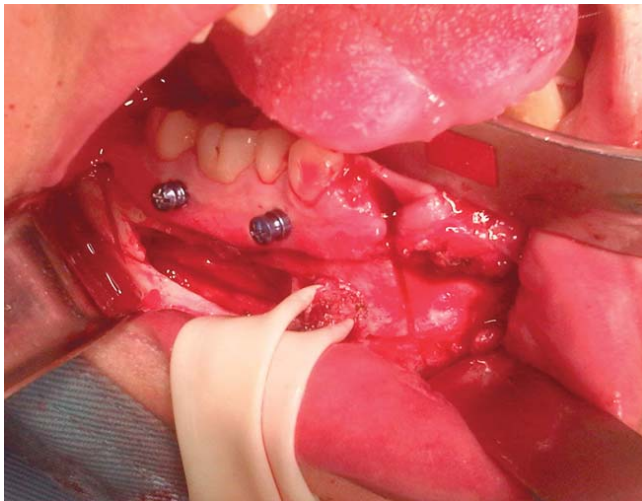


Figure 6. Surgery photograph. Cortical retirement, liberation of the mental nerve and osteotomy at the level of the parasymphysis.

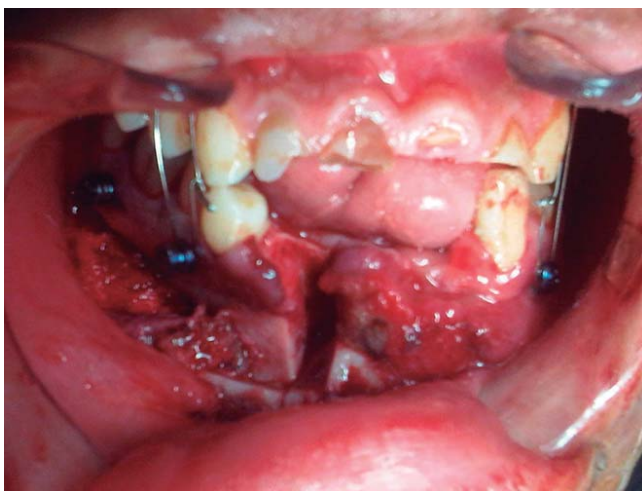


Figure 7. Surgery photograph. Mobilization of the alveolar segment in occlusion.

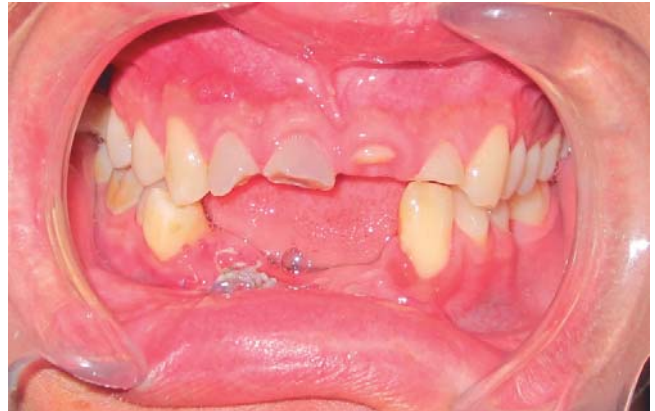

Figure 8. Intraoral photograph. Stable right posterior occlusion.

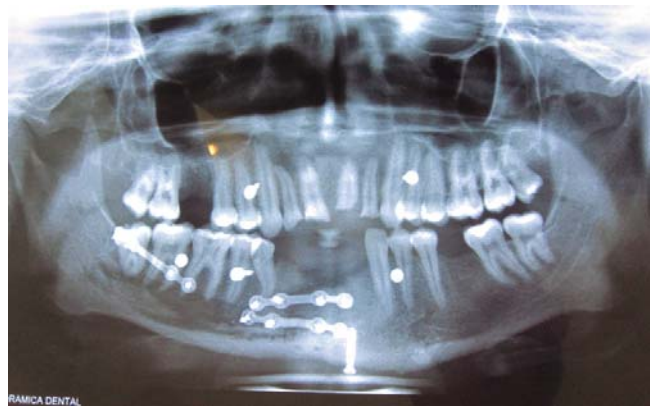


Figure 9. Postsurgical panoramic radiograph.

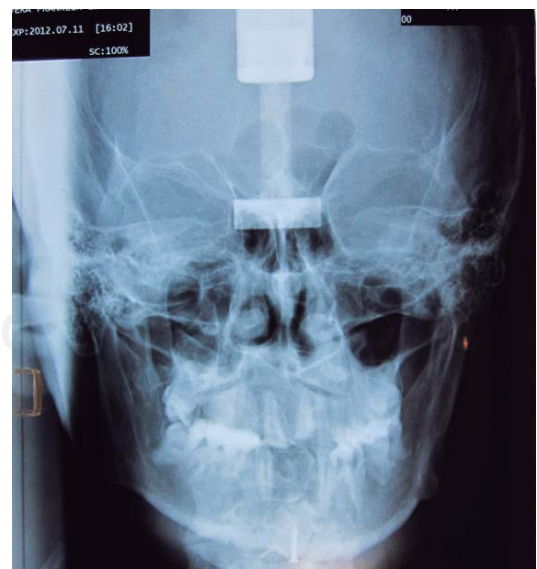

Figure 10. Posteroanterior radiograph. Symmetry is observed with scissor bite on the right side.

who handle this field. The treatment goals have to be headed towards recovering function and improving the aesthetics altered by the disease.

For correcting maxillary deformities several procedures of osteotomies have been described at the level of the mandibular body and ramus.¹² For cases where the patient presents an accentuated curve of Spee or Wilson, reduced or excessive alveolar space, alveolar asymmetry or an inadequate alveolar height. When the case exceeds the therapeutic indication for orthodontic treatment it is necessary to employ a technique of single or combined alveolar osteotomies.¹² In this case we used the modification made by Mohammed on the release of the cortical for mobilization of the dental nerve with direct vision.¹³

Distraction osteogenesis as a therapeutic option is indicated to correct complete segments with tissue deficiency. In this case the problem was focused on the position of the right mandibular alveolar process. Generally any segmental distraction requires a second surgery to remove the distractor and/or perform a corrective osteotomy to achieve the aim.³ Performing conventional orthognathic surgery with a bilateral sagittal mandibular technique generates a movement of both sides to compensate for the unilateral defect and may exacerbate the asymmetry or create a new one. We saw no need to intervene on both sides but use only a unilateral technique at alveolar level. Another option was re-fracture and mobilization: a process in which we have little control and high risk of nerve

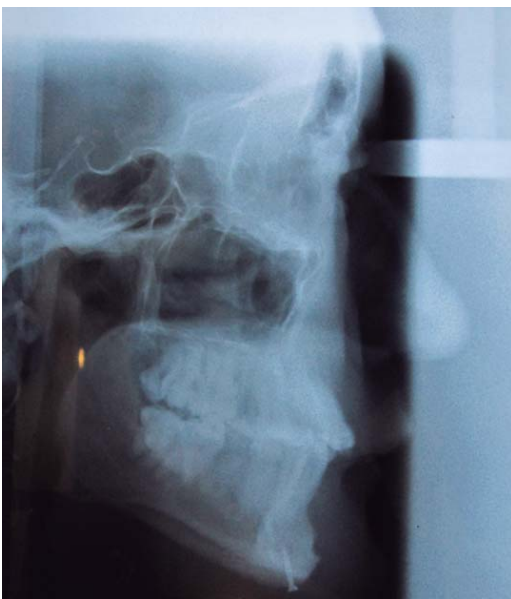

Figure 11. Lateral head film. Acceptable maxillofacial relationship. Screw in the mandibular symphysis.

damage. Re-fracture should preferably be performed anterior or posterior the bone callus because this tissue is more mineralized by the repair process.^{2,12}

In cases of severe asymmetries of the middle and lower third, the technique can be combined with conventional osteotomies, or bone grafting techniques, although as each case is different a consensus has not been reached.¹⁴ The traditional technique could not be applied due to the fact that it may result in a shift of the mandibular side towards the unaffected side thus creating a true facial asymmetry.^{7,14}

The risks of the technique are: damage the dental nerve, affect a root or create a periodontal defect.¹⁵ It should also be taken into consideration that it is technically laborious and delayed procedure.¹² It is highly recommended to use a piezo-electric scalpel when the incision is made in close proximity to the nerve, since this is an instrument of hard tissue selective cutting although the time needed for each incision may be excessive.¹⁶ The most common periodontal defect is located at the level of the approach and the new bone defect caused by alveolar displacement. Shultes reported 51 pathological periodontal injuries in 74 sites of segmental osteotomy and 35 in segmental areas with periodontal bone defects.^{17,18} Other studies by Dorfman and Turvey reported that segmental surgery might be completed without significantly affecting periodontal health and pulp.¹⁹ The risk of necrosis is low and surgical safety is based on the study by Bell in 1969 on bone revascularization after osteotomy.¹¹ There is also some concern regarding the possibility of de-vitalizing the mandibular teeth, but after an initial period of hyposthesia there is a full recovery of the sensitivity if the nerve has not been sectioned.³

Subapical surgery for the treatment of dentoalveolar deformities is an important tool and its application in the management of sequelae resulting from facial trauma is very valuable for restoring a good intermaxillary relationship as it was demonstrated in the case hereby presented. However studying the patient and planning of treatment is of great importance for implementing surgical techniques with safe margins. In the case described highly favorable results were observed in restoring the intermaxillary relationship and an adequate evolution of the patient was shown.

REFERENCES

1. Epker B, Stella J, Fish L. *Dentofacial deformities: integrated orthodontic and surgical correction*. Vol. 4. 2nd ed. St. Louis, MO: Editorial Mosby; 1986: pp. 244-245.
2. Gomes JA. Osteotomia mandibular subapical para correção de mordida cruzada. *Rev Bras Cir Craniomaxilofac*. 2012; 15 (1): 38-41.

3. Boye T, Doyle P, McKeown F, Sandler J. Total subapical mandibular osteotomy to correct class 2 division 1 dento-facial deformity. *J Craniomaxillofac Surg*. 2012; 40 (3): 238-242.
4. Handelman CS. The anterior alveolus: its importance in limiting orthodontic treatment and its influence on the occurrence of iatrogenic sequelae. *Angle Orthod*. 1996; 66 (2): 95-109; discussion 109-110.
5. Hullihen SP. *Case of elongation of the under jaw, and distortion of the face and neck, caused by a burn, successfully treated*. United States: J. W. Woods; 1849: p. 157.
6. Kole H. Surgical operations on the alveolar ridge to correct occlusal abnormalities. *Oral Surg Oral Med Oral Pathol*. 1959; 12 (5): 515-529.
7. MacIntosh RB. Total mandibular alveolar osteotomy. Encouraging experiences with an infrequently indicated procedure. *J Maxillofac Surg*. 1974; 2 (4): 210-218.
8. Eliades T, Hegdvedt AK. Orthodontic-surgical correction of a Class II, Division 2 malocclusion. *Am J Orthod Dentofacial Orthop*. 1996; 110 (4): 351-357.
9. Pangrazio-Kulbersh V, Berger JL, Kaczynski R. Stability of skeletal class II correction with 2 surgical techniques: the sagittal split ramus osteotomy and the total mandibular subapical alveolar osteotomy. *Am J Orthod Dentofacial Orthop*. 2001; 120 (2): 134-143.
10. Trauner R, Obwegeser H. The surgical correction of mandibular prognathism and retrognathia with consideration of genioplasty. I. Surgical procedures to correct mandibular prognathism and reshaping of the chin. *Oral Surg Oral Med Oral Pathol*. 1957; 10 (7): 677-689; contd.
11. Bell WH. Revascularization and bone healing after anterior maxillary osteotomy: a study using adult rhesus monkeys. *J Oral Surg*. 1969; 27 (4): 249-255.
12. Wolford LM, Moenning JE. Diagnosis and treatment planning for mandibular subapical osteotomies with new surgical modifications. *Oral Surg Oral Med Oral Pathol*. 1989; 68 (5): 541-550.
13. Mohamedh Ali R, Schache A, Walsh S, Sneddon K. Total mandibular subapical osteotomy: modification of the technique. *Br J Oral Maxillofac Surg*. 2009; 46 (7): 629-630.
14. Scolozzi P, Herzog G. Total mandibular subapical osteotomy and Le Fort I osteotomy using piezosurgery and computer-aided designed and manufactured surgical splints: a favorable combination of three techniques in the management of severe mouth asymmetry in Parry-Romberg syndrome. *J Oral Maxillofac Surg*. 2014; 72 (5): 991-999.
15. Park JU, Hwang YS. Evaluation of the soft and hard tissue changes after anterior segmental osteotomy of the maxilla and mandible. *J Oral Maxillofac Surg*. 2008; 66 (1): 98-103.
16. Schaaeren S, Jaquiéry C, Heberer M, Tolnay M, Vercellotti T, Martin I. Assessment of nerve damage using a novel ultrasonic device for bone cutting. *J Oral Maxillofac Surg*. 2008; 66 (3): 593-596.
17. Ueki K, Marukawa K, Shimada M, Alam S, Nakagawa K, Yamamoto E. The prevention of periodontal bone loss at the osteotomy site after anterior segmental and dento-osseous osteotomy. *J Oral Maxillofac Surg*. 2006; 64 (10): 1526-1531.
18. Schultes G, Gaggl A, Kärcher H. Periodontal disease associated with interdental osteotomies after orthognathic surgery. *J Oral Maxillofac Surg*. 1998; 56 (4): 414-417; discussion 417-419.
19. Dorfman HS, Turvey TA. Alterations in osseous crestal height following interdental osteotomies. *Oral Surg Oral Med Oral Pathol*. 1979; 48 (2): 120-125.

Mailing address:

Diego Esteban Palacios Vivar

E-mail: diegoepalaciosvivar@yahoo.com