



Efficacy of the nasal molding in patients with unilateral cleft lip and palate in newborn to 6-month-old patients

Eficacia del conformador nasal en pacientes con labio y paladar hendidos unilateral de recién nacidos a 6 meses

Nataly Lopera Restrepo,* José Ramón Hernández Carvallo,§ José Roberto Gómez Cruz^{||}

ABSTRACT

Objective: The aims of this research were to assess and describe the clinical changes in the nostril that shows depression and asymmetry in patients with unilateral cleft lip and palate (UCLP) treated with presurgical nasoalveolar molding (PNAM) in the Center of Medical Specialties of the State of Veracruz (CEMEV). **Material and methods:** An observational, descriptive, longitudinal and prospective cohort study was carried out. 15 patients with ages between 0 and 6 months were part of the study. Measurements of t nostril height, nostril width, nasal basal width and columella length were performed at three times (T1, T2 and T3). **Results:** The vertical, horizontal and nostril base lengths showed a significant decrease in the initial measurement (T1), presenting a close similarity with the healthy nostril, with only 0.8 mm of difference with the healthy nostril in the vertical dimension ($p \leq 0.000982$ t Wilcoxon); in a horizontal dimension, 5.02 mm ($p \leq 0.000023$ t Student) and compared with the measurements of the nasal base it was found that at T3 it decreased 51%, ($p \leq 0.00004$ t Student). This reflects the effectiveness of the nasal molding treatment for correcting the nasal asymmetry caused by a nasal, lip and alveolar cleft. **Conclusion:** Treatment with the PNAM is effective since it reduced by 50% at least nasal depression, compared with the initial and final measurements.

RESUMEN

Objetivo: El propósito de este estudio fue evaluar y describir cuáles son los cambios clínicos del ala nasal que presenta depresión y asimetría en los pacientes con labio y paladar hendidos unilateral, tratados con el moldeador nasoalveolar prequirúrgico en el Centro de Especialidades Médicas del Estado de Veracruz. **Material y métodos:** Se realizó un estudio observacional, descriptivo, longitudinal y prospectivo, estudio de una cohorte. Se analizaron 15 pacientes, con edades comprendidas de 0 a 6 meses de vida. Se realizaron mediciones en tres tiempos (T1, T2 y T3) de la longitud de la ventana de la nariz en sentido horizontal, vertical, base de la nariz y longitud de la columna. **Resultados:** Las longitudes vertical, horizontal y base nasal, presentaron una notoria disminución en las medidas iniciales (T1) indicando una mejor similitud y semejanza con el ala nasal sana, tan solo 0.8 mm de diferencia con el ala nasal sana en sentido vertical ($p \leq 0.000982$ t Wilcoxon); en sentido horizontal 5.02 mm ($p \leq 0.000023$ t Student) y comparando las mediciones de la base nasal se encuentra que en T3 disminuyó en un 51% ($p \leq 0.00004$ t Student). Esto hace referencia a que el tratamiento del conformador nasal es efectivo para la corrección de la asimetría nasal generada por las fisuras nasal, labial y alveolar. **Conclusión:** El tratamiento con el moldeador nasoalveolar prequirúrgico es efectivo al disminuir al menos un 50% la depresión nasal en las tres mediciones, comparando medidas iniciales y finales.

Key words: Unilateral cleft lip and palate, presurgical nasoalveolar molding, nasal asymmetry.

Palabras clave: Labio y paladar hendidos unilateral, moldeador nasoalveolar prequirúrgico, asimetría nasal.

INTRODUCTION

Cleft lip and palate is a craniofacial congenital anomaly that afflicts patients both physically and functionally. Incidence is variable according to geographical location and it may be related to socioeconomic status, cultural level, health services and quality of policies in health care as well as literacy and ethnic group. Worldwide there is an incidence of 1:500¹ and in Mexico the incidence is 1:750 live newborns per year.²

Facial development occurs between the fourth and twelfth week of intrauterine life by fusion of five facial processes or prominences: frontonasal prominence

* Orthodontics Specialist, UNAM.

§ Orthodontics Specialist. Head of the Orthodontics Program.

^{||} Methodology Consultant. Doctor in Internal Medicine.

Center of Medical Specialties of the State of Veracruz (CEMEV).

© 2016 Universidad Nacional Autónoma de México, [Facultad de Odontología]. This is an open access article under the CC BY-NC-ND license (<http://creativecommons.org/licenses/by-nc-nd/4.0/>).

This article can be read in its full version in the following page:
<http://www.medigraphic.com/ortodoncia>

and maxillary and mandibular prominences.³ Lack of fusion between these processes is what causes lip, alveolar and palatal clefts. Risk factors during gestation are: intake of drugs such as diazepam and phenytoin, emotional disturbances, maternal age of more than 40 years, diabetes and methrorragia during the first trimester.⁴

McNeil⁵ and Burston⁶ in England introduced the concept of early maxillary orthopedics for cleft treatment during the fifties. In 1984 Matsuo et al⁷⁻⁹ used cartilage-modeling techniques during the neonatal period to correct congenital deformities of cleft lip and nostrils. It wasn't until 1999 that Grayson¹⁰ described the presurgical nasoalveolar molding (PNAM), a well-accepted technique since it adequately molds the wing of the nose and gives it a more esthetic and functional form through modeling and changing the position of the immature and malleable nasal cartilages thus accomplishing an enlargement of the columella.¹¹⁻¹⁴

Nasal stents are devices that were designed under the biological basis of Roux theory¹⁵ that states that there is an intimate relationship between form, structure and function. This concept was later introduced by Dr. Moss in the 60's under his theory of functional matrix.¹⁶ This is the reason why before cheiloplasty, nasal molding modifies alar base depression caused by the cleft thus improving the tip of the nose and elongating the columella when used in early stages. Besides, they are also used in the subsequent stage of a primary rhinoplasty for relapse prevention in the recently molded wing of the nose while keeping the airway permeable and preventing the formation of surgical adhesences due to nasal secretions and scarring.^{12,13}

Early orthopedics must be managed in the three dimensions of space: vertical, sagittal and transverse. The nasal stent should be inserted in an obturator that stimulates the palatal processes and brings them together due to the presence of the acrylic and muscular forces. As a result nasal molding occurs and deformation of the nasal wall is reduced since the device stimulates and repositions the soft tissues and nasal cartilages.¹⁷⁻¹⁹ By bringing together the palatal processes, arch form is improved as well as tongue position; intraoral pressure is balanced and modification of the nasal tissues is facilitated in order to improve the results in the surgical primary closure of the lip. To achieve all this, a great deal of cooperation from the parents is required as well as a good fabrication procedure and placement of the device from the professional.¹⁸

The present study aimed to assess and describe the clinical changes in the nasal wing that presents

depression and asymmetry in patients with unilateral cleft lip palate at the Clinic of Craniofacial Anomalies of the CEMEV.

MATERIAL AND METHODS

Before beginning with data collection the study was reviewed and approved by an ethics committee assigned to it by the Head of Teaching of CEMEV. For conducting this study a sample of 15 patients with diagnosis of cleft lip and palate with ages between newborn and 6 months of age who attended the Center of Medical Specialties of the State of Veracruz (CEMEV) in the Clinic of Craniofacial Anomalies (CACF) for a period of 6 months was conformed. The inclusion criteria were: patients of both genders, patients with ages between newborn and 6 months old, patients with unilateral CLP who had depression of the nasal wing, parents wishing to cooperate in this study and who signed the informed consent, patients who received care in the CACF. The exclusion criteria were: patients who due to the distance of their residence could not attend regular appointments and fortnightly controls, patients who had already undergone cheiloplasty, patients with craniofacial syndromes, patients who did not require shaping of the nasal wing, patients with a prognosis of short life expectancy. The elimination criteria were: patients with a maximum of 2 missed appointments fortnightly, patients who did not follow the indications for use and those who did not show commitment with treatment.

Thursdays are the days for reception of patients with a diagnosis of CLP. Sample selection was made and the informed consents were signed. The clinical charts and photographs were obtained. In the same appointment an impression with condensation silicone was taken and a Friedman plate with hard auto-curable acrylic was initially constructed. A button was adhered to the plate with an angulation of 45°. Two Transpore[®] tapes were attached to the plate and then adhered to the cheeks with an angle of 45° to help hold the plate and direct the stimulation forces for the lip and palate fissure. Once the cleft has a width of less than 5 mm the PNAM is constructed (*Figures 1 and 2*). The PNAM has a wire that at its distal end has a ball of hard acrylic coated with soft acrylic for not tearing the soft tissues and that extends from the Friedman plate to the afflicted nostril. Fortnightly controls should be done to adapt the obturator or Friedman plate and/or the nasal stent. It was instructed to use Corega[®] or Fixodent[®] for plate fixation and for directing adequately the forces to the plate. Additionally, placement, use and

daily cleaning instructions were given to the patient's parents.

In this appointment the first measurements were taken and determined as T1 (initial), T2 (intermediate appointment) and T3 (final). The indication for placing the PNAM will be up until the age of 6 months before performing the first cheiloplasty (*Table I*).

The measurements were obtained by the main researcher clinically with a digital caliper and were collected in a data collection sheet along with the informed consent that has been previously signed (*Figure 3*).

RESULTS

Fifteen patients with ages between 0 and 6 months were analyzed. Age range upon beginning of treatment was from 0 to 90 days old, with a mean of 28 days and a S.D. of 27.7 days. The mothers' age range was

between 17 and 39 years old, mean age was 25.4 years with a S.D. of 6.33 years. Ten patients (66%) were male and five (33%) female. Fifty-three patients were affected on the left side and 47% on the right side. Treatment time was a mean of 109 days; the shortest treatment time was 45 days and the longest, 192 days. Nasal wing molding with the PNAM was accomplished in approximately 71.6 days.

Mothers began the folic acid intake in the first, second, third and fourth gestation months with a mean of 2.5. Thirty-three percent of the patients had a hereditary genetic component for their UCLP. In 53%

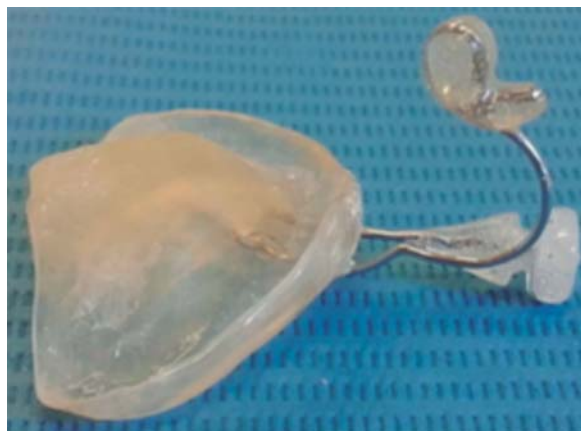

Figure 1. Constructed PNAM.

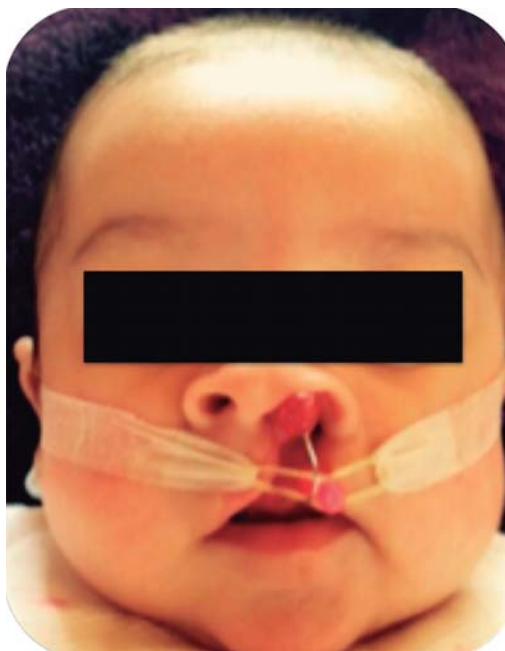

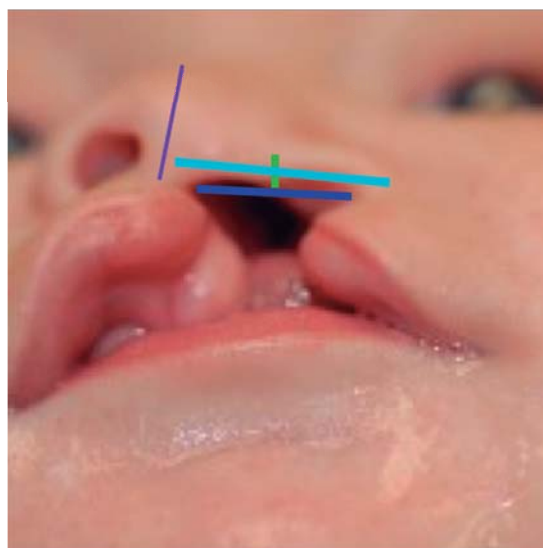
Figure 2. PNAM attached to the patient.

Table I. Definition of variables.

Variable	Definition
Age	Time elapsed between birth until the moment of initial consultation as registered in the clinical chart
Gender	As registered in the clinical chart
Vertical length of the nostril	Measurement from the highest point of the nostril perpendicular to a line from the base of the nostril as obtained by there searcher at T1, T2 y T3
Width of the nostril	Measurement from the external ridge to the internal ridge of the nostril as obtained by there searcher at T1, T2 y T3
Width of the base of the nose	Measurement from the most distal point of the base of the nose from lefttoright as obtained by there searcher at T1, T2 y T3
Columnella length	Measurement from the length of the tip of the nose to the nasal base performed by there searcher at T1, T2 and T3

of the cases, the first borne child had CLP, in 26% of the cases the second child was the one afflicted and in 21% of the cases, the third child was the one who suffered the malformation. Only 13% of the mothers had a threatened abortion during the first trimester. In 20% of the cases the mother declared having ingested penicillin or ampicillin during their first trimester of pregnancy during to a urinary infection. Others referred hypotension, anemia, flu, tobacco dependency and typhus.

The results of the measurements at the beginning of treatment, during and at the end of treatment, T1, T2, and T3 respectively are shown in *table II*. The means obtained from the measurements were compared at



	Nostril length
—	Nostril width
/	Columnella length
—	Nasal base width

Figure 3. References for obtaining the measurements.

T1, T2 and T3 for the variables: nostril length, nostril width, nasal base width and columnella length in both the healthy and the affected nostril. These data are shown in *table II*.

In *table II* the mean measurements obtained from the different variables may be observed. It compares the healthy nostril and the affected one and the difference between them. By comparing the mean length a difference of 2.21 mm in T1 was obtained, in T2 this difference decreased to 1.39 mm and in the final measurement there was a decrease of 0.8 mm thus suggesting that the nostrils are similar to one another.

Regarding width, at T1 a difference of 9.22 may be observed that decreases to 7.59 mm at T2 and at T3, it declines to 5.02 mm with respect to T1 thus suggesting an improvement in the shape of the affected nasal wing and bearing greater resemblance with the healthy nasal wing.

In the following *figures 4 to 6* it may be observed that during the course of treatment the length, width and nasal base length showed a noticeable decrease in the initial measurements (T1) thus indicating a better similarity and likeness with the healthy nostril. There was only a 0.8 mm difference with the healthy nasal wing in the vertical direction ($p < 0.000982$ t Wilcoxon); 5.02 mm ($p < 0.000023$ t Student) in a horizontal direction and by comparing measurements of the nasal base is that in T3 decreased in 4.2 mm ($p < 0.00004$ t Student). These results suggest that treatment with nasal molding is effective for the correction of the nasal asymmetry caused by the cleft lip palate.

Regarding columnella length, it may be observed in *figure 7* a progressive increase: it increases 1.57 mm ($p \leq 0.382353$ t Wilcoxon) at T3 when compared to T1. This result was expected due to the proper conformation of the afflicted nasal wing and the patient's own growth. When PNAM is used the columnella is not affected in unilateral cases.

Table II. Comparison of the means between the healthy and the afflicted sides and their differences.

Variables	T1			T2			T3		
	H	A	Dif	H	A	Dif	H	A	Dif
\bar{X} Length	4.22	2	2.21	4.56	3.16	1.39	5.38	4.57	0.8
\bar{X} Width	7.48	16.71	9.22	7.8	15.39	7.59	8.75	13.77	5.02
\bar{X} Nasal base L	12.38	20.99	8.6	13.52	19.8	6.27	14.46	18.66	4.2

Definitions: \bar{X} Length = mean length measured in mm; \bar{X} Width = mean horizontal length measured in mm; \bar{X} Nasal base L = mean nasal base length measured in mm; H = healthy; A = afflicted; Dif = difference in mm between the healthy and the afflicted side; T1 = initial measurement; T2 = intermediate measurement; T3 = final measurement.

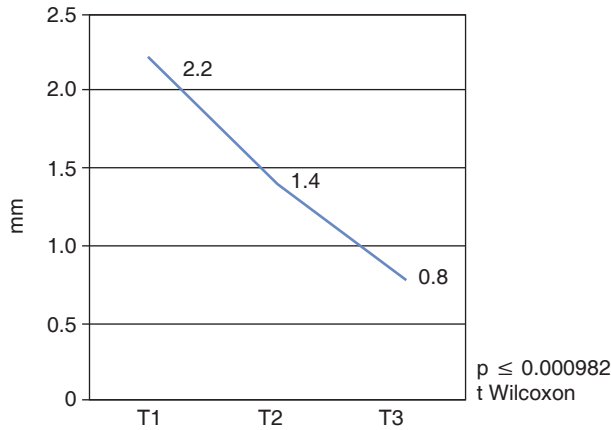


Figure 4. Difference between means at T1, T2, T3. \bar{X} Length.

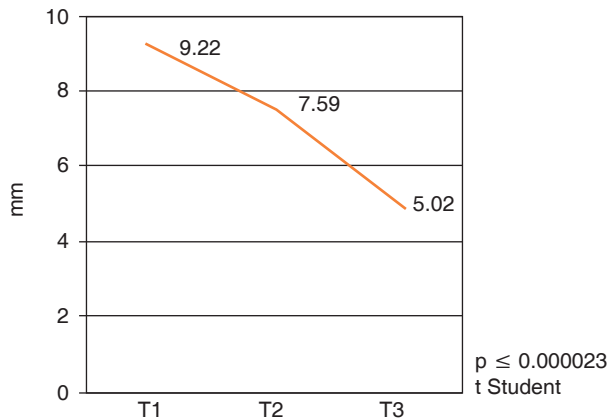


Figure 5. Difference between means at T1, T2, T3. \bar{X} Width.

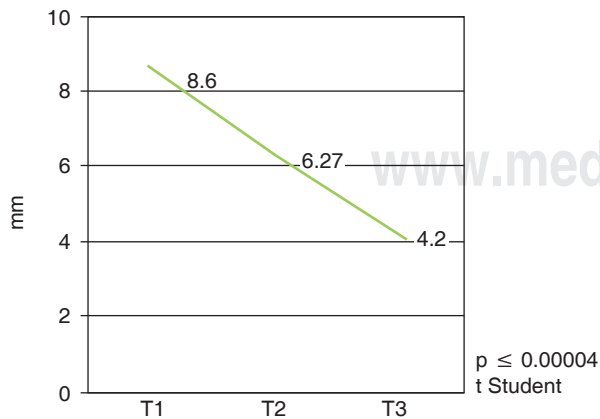


Figure 6. Difference between means at T1, T2, T3. \bar{X} Base.

DISCUSSION

Barry H. Grayson,²⁰ one of the pioneers in pre-surgical nasoalveolar molding, in his publication of 2001 described that the nasal stent combined with the molding plate achieves nasal and alveolar symmetry, good projection of the nasal tip and concluded that surgical repair would no longer be a challenge. Another study carried out by Maull¹¹ et al, similar to the one carried out in the CEMEV, concluded presurgical treatment with PNAM significantly decreases the asymmetry of the nose and the depressed nasal wing.

In the study published in 2010 by Mishra¹³ et al, 17 patients with unilateral CLP showed an increase in the height of the wing of the nose with the use of PNAM and also demonstrated that it is more effective at early ages, maximum 6 weeks after birth.

Chien-Jung¹⁴ in 2005 arrived at a similar conclusion to the one of the present study: that PNAM is an effective procedure that improves nasal symmetry in terms of width, nasal height and columella angle in patients with unilateral CLP.

Liou¹⁹ et al evaluated by means of photographs the changes that occurred in 25 patients with nasoalveolar molding and concluded that nasal asymmetry gradually improved significantly after the first surgery for primary closure of the lip or cheiloplasty and that a year after surgery, the changes remained stable and with good results. Although in this study stability was not investigated, we agree that pre-surgical treatment has excellent results in terms of nasal symmetry.

We accept the limitations of this study since it has a small sample size and a short-term follow-up and it also required collaboration with the parents and with other hospital services for proper recruitment of

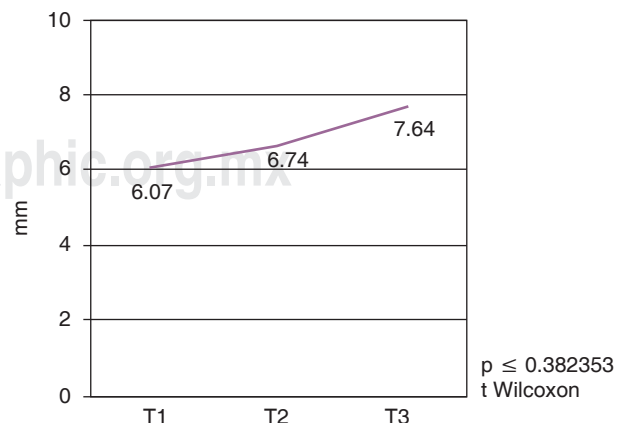


Figure 7. Difference between means at T1, T2, T3. \bar{X} Columella.

patients at early ages. It is essential to conduct follow-up studies of several years in order to assess more scientifically the stability of this treatment.

CONCLUSIONS

- Early use of nasoalveolar molding in neonates with CLP helps to shape, improve and decrease the size of the naso-alveolar-palatal fissure.
- Only at early ages, may good results be guaranteed in terms of conformation of the depressed nasal wing provided that parents collaborate and who follow the indications for use.
- Treatment with PNAM is effective to reduce at least by 50% the nasal depression caused by the cleft lip and palate, at the three measurements, comparing initial and final measurements.

REFERENCES

1. Morales C. Prevalencia de hendiduras labio palatinas. *Acta Odontol Venez.* 1992; 30: 35-40.
2. Trigos I, Guzmán M. Análisis de la incidencia, prevalencia y atención del labio y paladar hendido en México. *Cir Plast.* 2003; 13 (1): 35-39.
3. Sadler W. *Embriología médica con orientación clínica.* 9a edición. Madrid: Panamericana; 2004.
4. Corbo M, Marimón M. Labio y paladar fisurado. Aspectos generales que se deben conocer en la atención primaria de salud. *Rev Cubana Med Gen Integr.* 2001; 17: 379-385.
5. McNeil C. Orthodontic procedures in the treatment of congenital cleft palate. *Dent Rec.* 1950; 70: 126-132.
6. Burston WR. The early treatment of cleft palate conditions. *Dent Pract.* 1958; 9: 41-56.
7. Matsuo K, Hirose T, Tonomo T. Nonsurgical correction of congenital auricular deformities in the early neonate: a preliminary report. *Plast Reconstr Surg.* 1984; 73: 38-50.
8. Matsuo K, Hirose T, Otagiri T, Norose N. Repair of cleft lip with nonsurgical correction of nasal deformity in the early neonatal period. *Plast Reconstr Surg.* 1989; 83: 25-31.
9. Matsuo K, Hirose T. Preoperative non-surgical over-correction of cleft lip nasal deformity. *Br J Plast Surg.* 1991; 44: 5-11.
10. Grayson B, Santiago P, Brecht L, Cutting C. Presurgical nasoalveolar molding in patients with cleft lip and palate. *Cleft Palate Craniofac J.* 1999; 36: 486-498.
11. Maul D, Grayson B, Cutting C, Brecht L, Bookstein F, Khorrambadi D et al. Long-term effects of nasoalveolar molding on three-dimensional nasal shape in unilateral clefts. *Cleft Palate Craniofac J.* 1999; 36: 391-397.
12. Ömer S, Sament V. Anovel nostril retainer designed by a patient. *Aesth Plast Surg.* 2009; 33: 789-790.
13. Mishra B, Sing A, Zaidi J, Singh G, Agrawal R, Kamar V. Presurgical nasoalveolar molding for correction of cleft lip nasal deformity: experience from northern India. *Plast Surg J.* 2010; 10: 443-456.
14. Chien-Jung B, Wen-Ching E, Shing C, Wein E. Symmetry of the nose after presurgical nasoalveolar molding in infants with unilateral cleft lip and palate: a preliminary study. *Cleft Palate Craniofac J.* 2005; 42: 658-663.
15. Frankel R. Revista electrónica consultada el día 30 enero de 2013. Disponible en: <http://www.amom.com.mx/amominfo1.htm>
16. Moss M. The primary role of functional matrices in facial growth. *Am J Orthod.* 1969; 55: 566-577.
17. Muñoz A, Castro L. Ortopedia tridimensional y manejo preoperatorio de tejidos blandos en labio paladar hendidos. *Cir Plast.* 2008; 1: 6-12.
18. Proffit W. *Ortodoncia contemporánea.* 4a edición. España: Elsevier Mosby; 2008. pp. 321-327.
19. Liou E, Subramanian M, Chen P, Huang C. The progressive changes of nasal symmetry and growth after nasoalveolar molding: a three-year follow-up study. *Plast Reconstr Surg.* 2004; 114: 858-864.
20. Grayson B, Santiago P, Brecht L, Cutting C. Presurgical nasoalveolar molding in patients with cleft lip and palate. *Cleft Palate Craniofac J.* 1999; 36: 486-498.

Mailing address:

Nataly Lopera Restrepo

E-mail: elniloazul@hotmail.com,
ledzepzoso4@gmail.com