



## Camouflage orthodontic treatment in a skeletal class III patient with a missing upper canine

### *Tratamiento ortodóncico camuflaje de paciente clase III esquelética con ausencia de canino superior*

Karla Yeraldí Mariscal García,\* Hugo Alberto Vásquez Estrada,§ José Ramón Hernández Carvallo<sup>||</sup>

#### ABSTRACT

Camouflage orthodontic treatment is an acceptable option for mild to moderate skeletal discrepancies for correcting the malocclusion and at the same time the skeletal problem. In this article, a case report of a camouflage orthodontic treatment in a skeletal class III patient with anterior crossbite, bilateral molar class III, bilateral non assessable canine class and absence of an upper canine is presented. The aim of this article is to show that orthodontic camouflage is an acceptable treatment option on the daily practice for mild skeletal discrepancies that offers esthetic results in the soft tissues as well as the correction of the malocclusion.

**Key words:** Orthodontic camouflage, skeletal class III malocclusion, malocclusion.  
**Palabras clave:** Camuflaje ortodóncico, clase III esquelética, maloclusión.

#### RESUMEN

El camuflaje ortodóncico es una alternativa viable para el tratamiento de discrepancias esqueléticas de leves a moderadas de las estructuras maxilares, corrigiendo la maloclusión y al mismo tiempo el problema esquelético. En este artículo se presenta un caso clínico de tratamiento ortodóncico con camuflaje de una clase III esquelética, mordida cruzada anterior, clase III molar bilateral, clase canina no valorable bilateral y ausencia de canino superior izquierdo. El objetivo de este artículo es mostrar que el camuflaje ortodóncico para discrepancias esqueléticas leves es una opción de tratamiento en la práctica diaria, obteniendo resultados estéticos favorables en tejidos blandos y resolviendo la maloclusión.

#### INTRODUCTION

Skeletal class III malocclusion occurs when there is discrepancy in size or position of the maxillae; it can occur by an alteration of the maxilla, the mandible or a combination of both.<sup>1</sup>

For any kind of skeletal class III malocclusion Proffit<sup>2</sup> states that there are three treatment options:

- 1) Growth modification, whenever possible.
- 2) Camouflage of the skeletal discrepancy through tooth movements, so as to correct the dental occlusion even though the skeletal discrepancy is maintained, or
- 3) surgical correction.

Due to the fact that in the adult patient growth has ceased, treatment options are reduced to two possibilities: camouflage or orthognathic surgery. The key question in treatment planning for an adult with a class III skeletal malocclusion is to find out if camouflage is a realistic option or not. The answer must be based on the required orthodontic movements, the stability of these changes and whether or not the probable esthetic outcome complies with the patient's

expectations. On the basis that in the adult patient there is no growth, the therapeutic decision is easier than in a teenager but we should always keep in mind that the psychological factors are more complex in adult patients looking for orthodontic treatment. Therefore, it becomes extremely important to have a clear idea of what are the wishes and expectations of our patient.<sup>1,3,4</sup>

By everything previously discussed, orthodontic camouflage in class III malocclusions is a realistic option only if the skeletal discrepancy is mild.

As a general rule, Proffit<sup>2</sup> defines precise indicators in order to consider a class III problem too serious to be treated with orthodontics only. Thus, a negative overjet of more than 3 mm or a difference between

\* Third year Resident of the Orthodontics Specialty Program.

§ Professor of the Orthodontics Specialty Program.

<sup>||</sup> Head of the Orthodontics Specialty Program.

Medical Specialties Center of the State of Veracruz (CEMEV).

This article can be read in its full version in the following page:  
<http://www.medigraphic.com/ortodoncia>

point A and point B projected on the anterior skull base greater than -2 mm indicates that the discrepancy might be too large to be solved solely and exclusively with orthodontics and that we must think in terms of some sort of surgical procedure. Similarly, hyperdivergent facial patterns (with a tendency to open bite) have worse prognosis than those that are more convergent.<sup>5</sup>

From our point of view, we should treat skeletal class III patients with camouflage orthodontic treatment based both in hard and soft tissues. On the other hand, we believe that the perception of facial esthetics by the patient himself is vitally important and will be crucial when it comes to decide for a conservative or a surgical therapy.

The risks and benefits of both orthodontic treatment and the surgical option must be carefully analyzed. Camouflage requires longer treatment time and higher cooperation, but surgery may be more expensive and have a higher risk. It is very important to explain to the patient the pros and cons of both options so that they understand the treatment make a totally objective decision.<sup>6,7</sup>

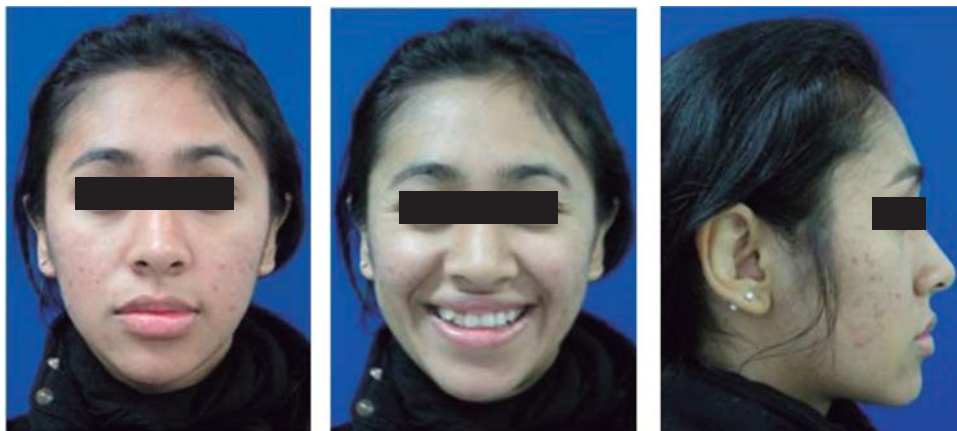
### MATERIAL AND METHODS

Female patient, 21 years of age who attends the Orthodontics Clinic in the «Dr. Rafael Lucio» Medical Specialties Center of the state of Veracruz. The reason for consultation was «I want to straighten my teeth» as referred by the patient, and the diagnosis was:

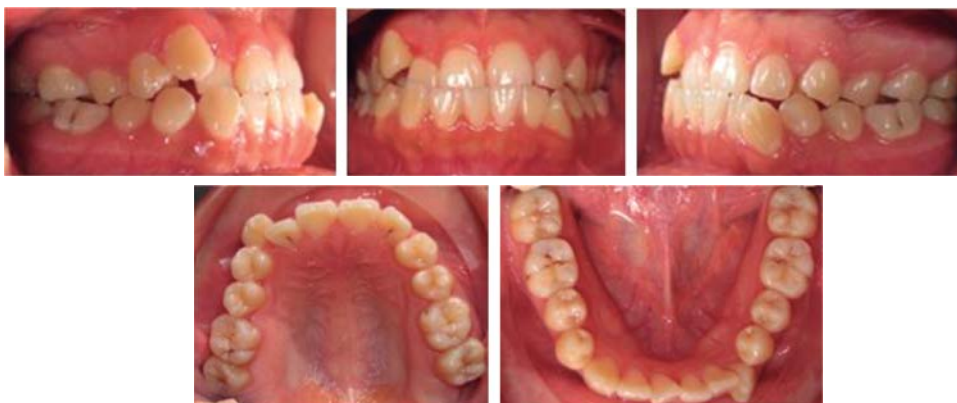**Extraoral analysis:** dolichofacial biotype, oval-shaped face, straight profile, retrusive middle facial third, thick lips, straight nose (*Figure 1*).

**Intraoral analysis:** bilateral molar class III, non-assessable canine class on the right side due to supra-occlusion of the canine and on the left side, due to supra-occlusion of the canine and on the left side, due to supra-occlusion of the canine. She also presented an anterior crossbite with a negative overjet of 1.5mm and a cuspid to cuspid relation from the upper left first premolar to the upper left first molar (*Figure 2*).

**Radiographic analysis:** in the cephalometrics, the patient was diagnosed as a skeletal class III due to the mandible; upper incisor proclination and mandibular body length increased. In the panoramic radiograph, an absence of the upper and lower third molars is



**Figure 1.**  
Initial facial photographs.



**Figure 2.**  
Initial intraoral photographs.

observed as well as of the upper left canine and no pathology in the hard tissues (*Figure 3*).

### Treatment plan

A camouflage orthodontic treatment for the skeletal class III was performed by placing 0.022" X 0.028" slot MBT fixed appliances.

Extraction of 3 first premolars (14, 34, 44) was indicated to relieve crowding and correct the anterior

cross-bite, by retracting the lower anterior segment, first, the lower canines and afterwards, the four incisors with a 0.016" SS archwire and 5/16" 4 oz. class III elastics. Once a positive overbite and overjet was achieved a 0.019" X 0.025" NiTi archwire was placed, followed by a 0.019" X 0.025" stainless steel archwire (*Figure 4*).

For the posterior segment, a lingual button and cross elastics were used.

Anchorage in the lower dental arch was achieved with a lingual arch.

Retention was carried out with Hawley type plates in both arches. The total treatment time was one year and eight months.

### RESULTS

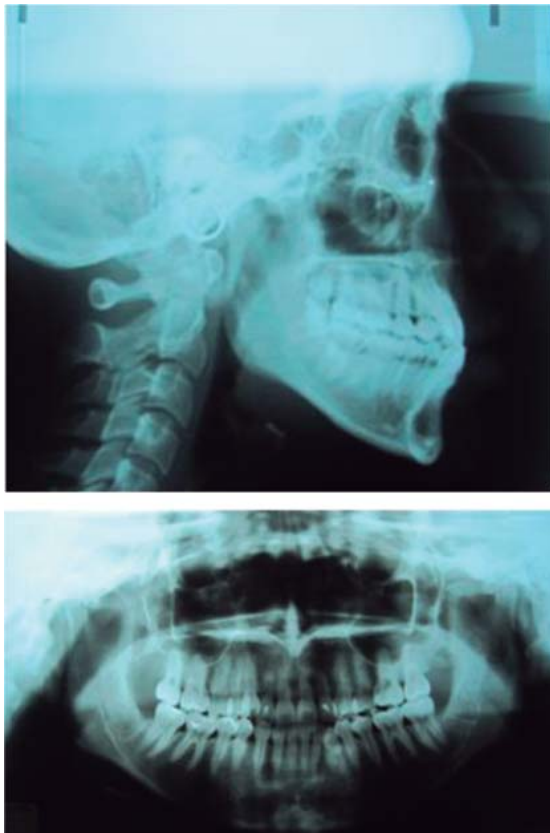With this treatment, an improvement in the soft tissues was obtained giving the patient a better lip projection, an adequate function of the upper left premolar and canine, canine and molar class I on both sides, aligned dental midlines, improvement of the smile, a positive overbite and overjet, periodontal health and proper occlusal function (*Figures 5 to 8*).

It was suggested to the patient to have an interconsultation with the Oral Rehabilitation specialist and the Periodontist to characterize the upper premolar as canine, as well as to restore the incisal edges of the upper central incisors and perform a crown lengthening in these same dental organs to improve the aesthetics.

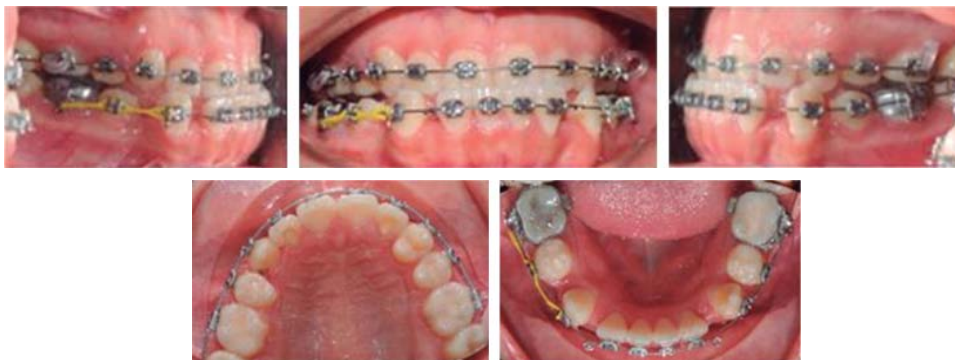### DISCUSSION

Orthodontic camouflage of skeletal class III malocclusions has been a controversial topic due to the limitations that this treatment might have, however, with proper knowledge and diagnosis the stated objectives can be achieved at the end of treatment.<sup>8,9</sup>

The notable improvement in the profile, smile and occlusion of the patient is an important point

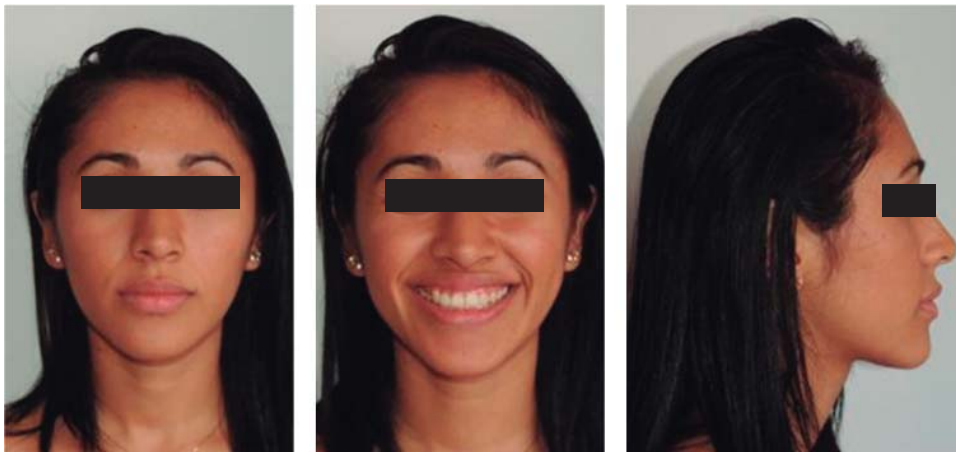


**Figure 3.** Initial radiographs.



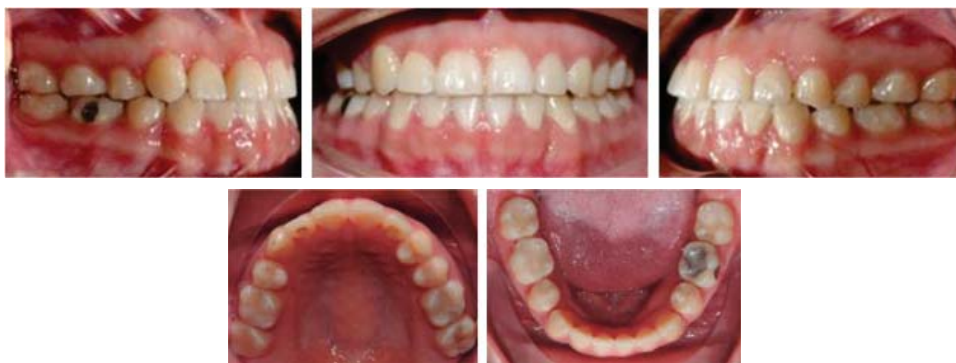**Figure 4.**

Intraoral photographs during treatment.



**Figure 5.**

Final facial photographs. Note the improvement in the patient's profile and smile.



**Figure 6.**

Final intraoral photographs. Note the improvement in the overjet and overbite as well as in the posterior relationship.

to emphasize as this had mayor influence on the personal and social development of the patient who acquired more security and self-esteem. This has to do with the psychological aspect of the case and the importance of orthodontics on this matter by providing the possibility of changing our patients' social role.

To perform an orthodontic treatment in order to compensate for minor discrepancies in the jaws is an excellent therapeutic option provided there is a proper diagnosis and a successful treatment plan. This option provides convincing results for both the orthodontist and the patient, freeing the latter from being subjected to a surgical procedure which may include an increased economic cost and the inherent risks of general anesthesia as well as those of the intervention itself.<sup>10,11</sup>

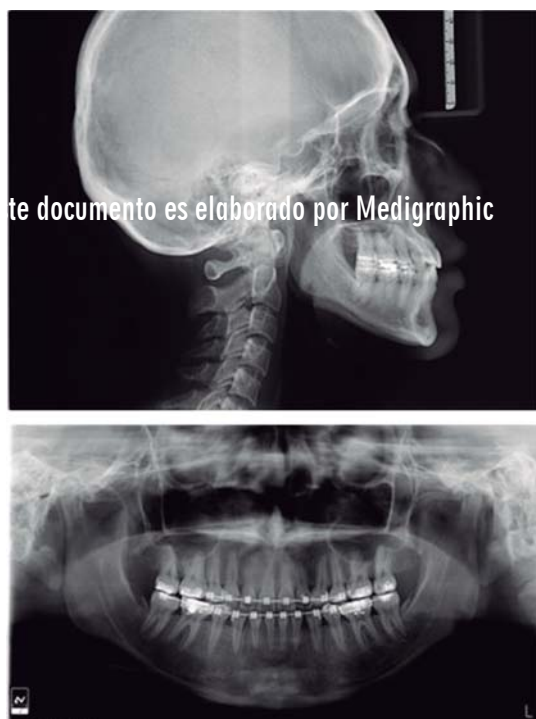For Mihalik and Proffit (2003),<sup>12</sup> the most important decision to make between camouflage or surgery should be based on whether or not the dentofacial cosmetic improvement accomplished with surgery is worth the increase in the treatment cost and the risk it poses to the patient. The risks of the surgery can obviously be much larger than those that occur in patients treated with camouflage.

The clinical case hereby presented did not exhibit a severe dento-skeletal discrepancy so it was possible to perform an orthodontic camouflage to decrease the problem both aesthetically and functionally since not all cases can be corrected or dentally compensated.

Sadao<sup>9</sup> mentioned that in a skeletal and dental class III camouflage, he performed extractions of the upper second premolars and lower first premolars with the purpose of obtaining a molar class I. It is worth mentioning that in his case report there was no crowding, however, in our patient lower first premolar and upper right first premolar extractions were carried out due to the absence of the upper canine and the severe crowding. It is important to mention that this kind of decisions is entirely dependent of the diagnosis made for each patient.

## CONCLUSIONS

Orthodontic camouflage has its limitations, since it involves solving a dento-skeletal problem through tooth movements only. The camouflage orthodontic treatment in this patient was successful due to a combination of factors: cooperation, proper diagnosis



**Figure 7.** Final radiographs.

and a carefully executed treatment plan, as well as the initial dento-skeletal characteristics of the patient that fell within the parameters susceptible of being corrected through orthodontic biomechanics. Orthognathic surgery was avoided with the times, risks and costs that it implies.

#### REFERENCES

1. Canut JA. Clase III. Ortodoncia clínica y terapéutica. CanutBrusola JA. ed. Barcelona: Masson. 2005. pp. 599-635.
2. Proffit W. Ortodoncia contemporánea. 4a. Ed. España: Edit. Elsevier Mosby 2008. pp. 686-718.
3. Burns et al. Class III camouflage treatment. What are the limits? *Am J Orthod Dentofacial Orthop.* 2010; 137: 9-13.
4. Spalj S, Mestrovic S, Lapter VM, Slaj M. Skeletal components of class III malocclusions and compensation mechanisms. *J Oral Rehabil.* 2008; 35 (8): 629-637.
5. Ellis E, McNamara J. Components of adult class III open-bite malocclusion. *Am J Orthod.* 1984; 86 (4): 277-290.
6. Proffit WR, Phillips C, Douvartzidis N. A comparison of outcomes and surgical-orthodontic treatment of class II malocclusion in adults. *Am J Orthod.* 1992; 101: 556-65.
7. Tseng Y, Pan C, Chou S, Liao C, Lai S, Chen C et al. Treatment of adult class III malocclusions with orthodontic therapy or orthognathic surgery: receiver operating characteristic analysis. *Am J Orthod Dentofacial Orthop.* 2011; 139 (5): 485-493.
8. Janson G, Souza JE, Alves Fde A, Andrade P Jr, Nakamura A, de Freitas MR. Extreme dentoalveolar compensation in the treatment of Class III malocclusion. *AJODO.* 2005; 128: 787-794.
9. Sadao S. Case report: Developmental characterization of skeletal class III malocclusion. *Angl Orthod.* 1994; 64 (2): 105-111.
10. Kochel J, Emmerich S, Meyer-Marcotty P, Stellzig-Eisenhauer A. New model for surgical and nonsurgical therapy in adults with Class III malocclusion. *Am J Orthod Dentofacial Orthop.* 2011; 139 (2): 165-174.
11. Daher W, Caron J, Wechslerc MH. Nonsurgical treatment of an adult with a class III malocclusion. *AJODO.* 2007; 132: 243-251.
12. Mihalik CA, Proffit WR, Phillips C. Long-term follow-up of Class II adults treated with orthodontic camouflage: a comparison with orthognathic surgery outcomes. *Am J Orthod Dentofacial Orthop.* 2003; 123 (3): 266-278.



**Figure 8.** Pre and post-treatment cephalometric superimposition.

Mailing address:  
**Karla Yeraldí Mariscal García**  
 E-mail: lalamarga@hotmail.com