



Orthodontic-surgical management of a patient with class II division 2 malocclusion and prominent chin

Manejo ortodóncico-quirúrgico de un paciente con maloclusión clase II división 2 y mentón prominente

Sayra Nayelli Velázquez Serrano,* Antonio Gómez Arenas§

ABSTRACT

Male patient of 13 years of age, skeletal class II with horizontal growth and prominent chin, whose main reason for consultation was his prominent chin who presented a concave profile, brachifacial biotype, lower retrocheilia, prominent chin, horizontal growth, deep mentolabial fold. He had a class II division 2 malocclusion, a 4 mm overjet and a 6 mm overbite. The treatment objectives were to improve the facial and dental aesthetics, coordinate dental arches and establish a functional occlusion. Interdisciplinary treatment was performed (orthodontic-orthognathic surgery), beginning with a pre-surgical phase by placing .022 slot MBT fixed appliances. In the surgical phase, a triple surgery was performed and subsequently, a postsurgical stage. Treatment results were satisfactory since the set out objectives were achieved thus improving the patient's facial aesthetics. Interdisciplinary communication is important as well as to recognize the patient's expectations in order to perform a good diagnosis and select the treatment alternative that best favors function, aesthetics and improves the patient's self-confidence.

RESUMEN

Paciente masculino de 13 años de edad, clase II esquelética, con crecimiento horizontal y mentón prominente, cuyo principal motivo de consulta era el mentón prominente existente. Presenta perfil cóncavo, braquifacial, retroquelia inferior, mentón prominente, crecimiento horizontal, surco mentolabial muy marcado, dentalmente es clase II división 2, sobremordida horizontal 4 mm y sobremordida vertical 6 mm, mordida profunda. Los objetivos fueron mejorar la estética facial y dental, relacionar arcadas, establecer una oclusión funcional. El tratamiento realizado fue interdisciplinario (ortodóncico-quirúrgico), se inició con la fase prequirúrgica colocando aparatología fija MBT slot .022. En el tiempo quirúrgico se realizó una cirugía triple y posteriormente la fase postquirúrgica. Los resultados del tratamiento fueron satisfactorios, debido a que se consiguieron los objetivos planteados, mejorando estética y facialmente al paciente. Es importante la comunicación interdisciplinaria y las expectativas del paciente para llevar a cabo un buen diagnóstico y tomar la mejor alternativa de tratamiento; favoreciendo la función, estética y proporcionando seguridad personal al paciente.

Key words: Class II division 2, facial aesthetics, prominent chin, deep bite, interdiscipline.

Palabras clave: Clase II división 2, estética facial, prominencia del mentón, mordida profunda, interdisciplina.

INTRODUCTION

Aesthetics is the main motivational reason for patients seeking orthodontic treatment due to the fact that perception of the facial profile and dental aesthetics are essentially based on how people perceive themselves, however, people's emotions, thoughts and behavior may vary and these differences create individuality.¹ Some studies have argued that psychological factors may have certain effects on facial perception and dental aesthetics among young adults.^{1,2}

Class II malocclusions can pose a challenge for the diagnosis and treatment plan due to the fact that clinical features may hinder the cause of the malocclusion, and this may be because the maxilla is narrower than in adults with normal occlusion.^{3,4} The literature has mentioned that in patients with dentoskeletal disharmonies (class II), growth is different compared to

patients with a normal dentoskeletal relationship, both in quantity as well as in direction of the craneofacial structures.⁵

In 1899, class II division 2 malocclusion was defined by Angle. It has a relatively low prevalence in comparison with other malocclusions. This malocclusion is generally characterized by retroclined upper central incisors, deep bite and molars and canines in distocclusion.⁶⁻¹⁰

* Graduated of the Specialty of Orthodontics.

§ Professor of Orthodontics.

Postgraduate Studies and Research Division, Faculty of Dentistry, National Autonomous University of Mexico.

This article can be read in its full version in the following page:
<http://www.medigraphic.com/ortodoncia>

Etiology is multifactorial as there may be genetic or environmental factors involved or it may be due to a high lip line, lip hyperactivity or increased masticatory forces.¹⁰⁻¹³

Usually, patient's with this malocclusion have a mesofacial or brachyfacial biotype, many show a normal facial convexity and a straight or convex profile. Although they may have anti-aesthetic facial proportions and occlusal disharmonies, their mandibular ramus is normal or long and they have good growth potential of the mandible, sometimes even similar to patients with class I malocclusions.^{9,11-13}

However, the maxilla and mandible are the main bony bases of facial composition, therefore, the relationship between them, their occlusion and soft tissues define facial esthetics.¹⁴

Likewise, assessment of facial balance and harmony includes an analysis of the facial profile, therefore, the relationship between nose, lips and chin may be altered by growth and is important for a proportionate facial appearance.^{14,15}

This article describes the clinical case of a male patient of 13 years of age, who presented a class II division 2 malocclusion and a very prominent chin being the latter the main reason for consultation.

CLINICAL CASE

Male patient, 13 years of age who attended the Orthodontics Department at the Division of Postgraduate Studies and Research (DEPeI) of the National Autonomous University of Mexico (UNAM) and whose main reason for consultation was «I have a very large chin».

Cephalometrically, he was a brachycephalic skeletal class II and presented a retrusive lower lip, concave profile, prominent chin, short anterior cranial base, horizontal growth, upper incisor proclination and protrusion and lower incisor retroclination and retrusion (*Figure 1*). The panoramic radiograph (*Figure 2*) reveals a 2:1 crown-root ratio, adequate alveolar ridge height, presence of four third molars and short roots in the upper anterior teeth which was confirmed with periapical radiographs (*Figure 3*).

Facially, the patient had a concave profile, prominent chin, straight nose, deep mentolabial fold, protrusive upper lip, wide buccal corridors, upper incisor display when smiling (*Figure 4*).

At the intraoral clinical examination and orthodontic analysis, the patient presented a class II division 2 malocclusion, upper incisor proclination and protrusion, lower incisor retroclination and retrusion, bilateral molar class II and canine class I, increased overbite

and overjet, squared dental arches, molar rotation, excessive curve of Spee, severe upper and mild lower crowding, negative discrepancies between basal bone length and tooth material, bilateral molar and canine class II, increased overbite and overjet (*Figure 5*).

Treatment objectives

Skeletal class I with as much improvement of the profile as possible, eliminate dental crowding,

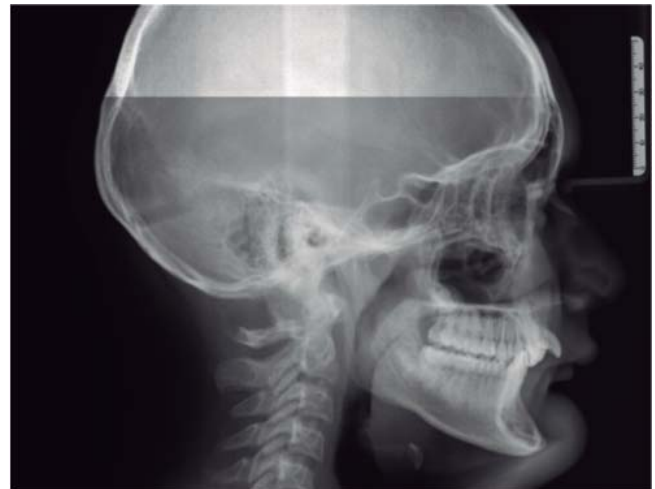

Figure 1. Initial lateral cephalogram.

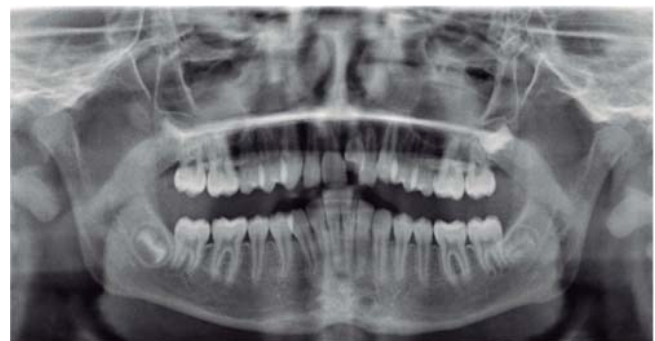

Figure 2. Initial orthopantomography.

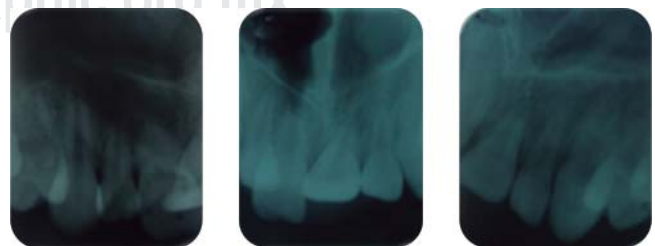

Figure 3. Periapical radiographs where a diminished root length was observed.

coordinate arches, achieve molar and canine class I as well as establish an adequate overbite and overjet and correct the dental midline.

Treatment plan

Orthodontic-surgical treatment, 0.022 slot MBT fixed appliances with bands in first and second upper and lower molars were placed.

Presurgical phase: initial leveling and alignment, coordination of dental arches, root correction and parallelization, closure of spaces.

Surgical phase: surgical prediction in conjunction with the department of surgery.

Postsurgical stage: re-leveling, bracket re-position, consolidation, stabilization, smile detailing and retention.

Course of treatment

Treatment was begun with the placement of 0.022-slot MBT fixed appliances, starting with the leveling and alignment (*Figure 6A*), the dental organ #22 was gradually incorporated, conforming the dental arches.

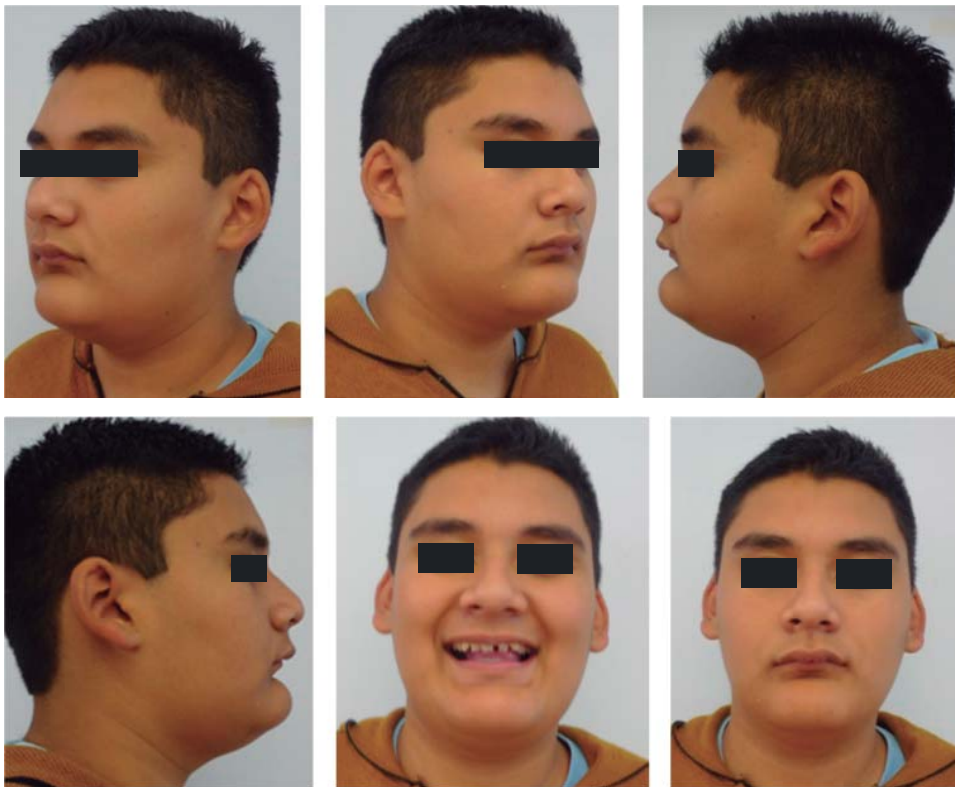

Figure 4.

Initial facial photographs.

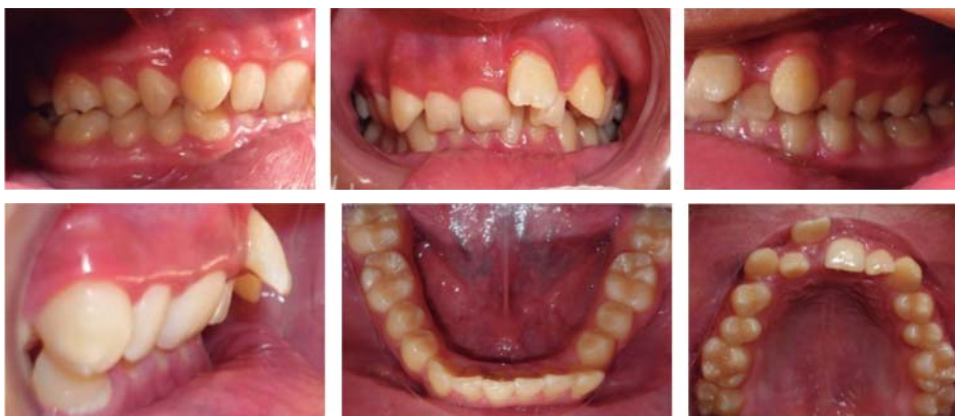

Figure 5.

Initial intraoral photographs.

Upper expansion was performed with a 0.032 wire in the accessory molar tubes (*Figure 6B*). The patient was referred to the Department of Surgery, where the case was assessed and the surgical prediction and model surgery were performed in an interdisciplinary way (*Figure 6c*).

In the maxilla, a Le Fort I osteotomy with a downward reposition was performed. The maxilla was segmented into three parts (3 mm); in the mandible, a 3 mm advancement was made and the chin was repositioned downwards 6 mm (*Figure 7*).

Follow-up appointments were scheduled at day 7, 15 and a month after the surgical procedure (*Figure*

8). 3.5 ounces, 5/16" intermaxillary elastics were used for 3 months for fixation, and afterwards, class II ¼" 3.5 ounces elastic were used. Subsequently, brackets of the dental organs #11, 22 and 12 were repositioned. Three months after the reposition appointment, fixed appliances were removed (*Figure 9*).

Retention: upper and lower circumferential retainers were placed.

RESULTS

Treatment objectives were accomplished: cephalometrically, skeletal class I was achieved; facially, the profile improved. Occlusally dental

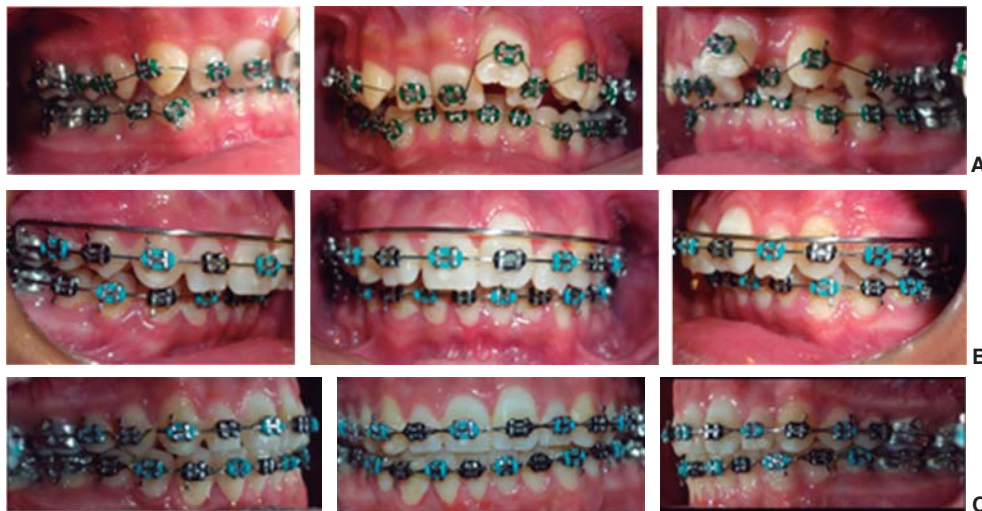

Figure 6.

A Leveling and alignment. **B** Expansion with 0.032 stainless steel archwire. **C** Occlusal Settlement.

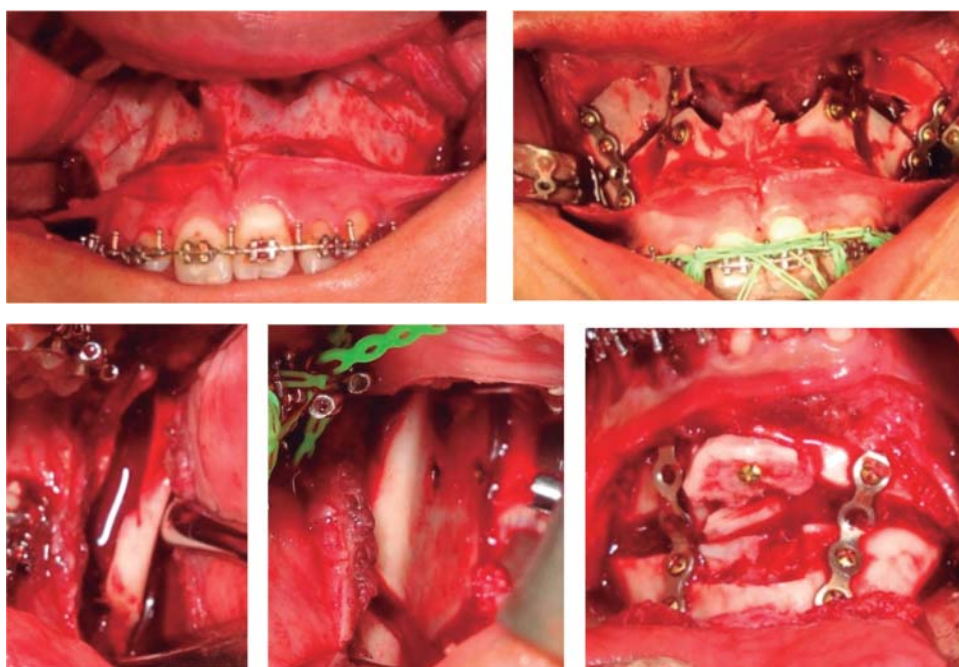


Figure 7.

Surgical procedure. Courtesy. MFS Anabella Hernandez

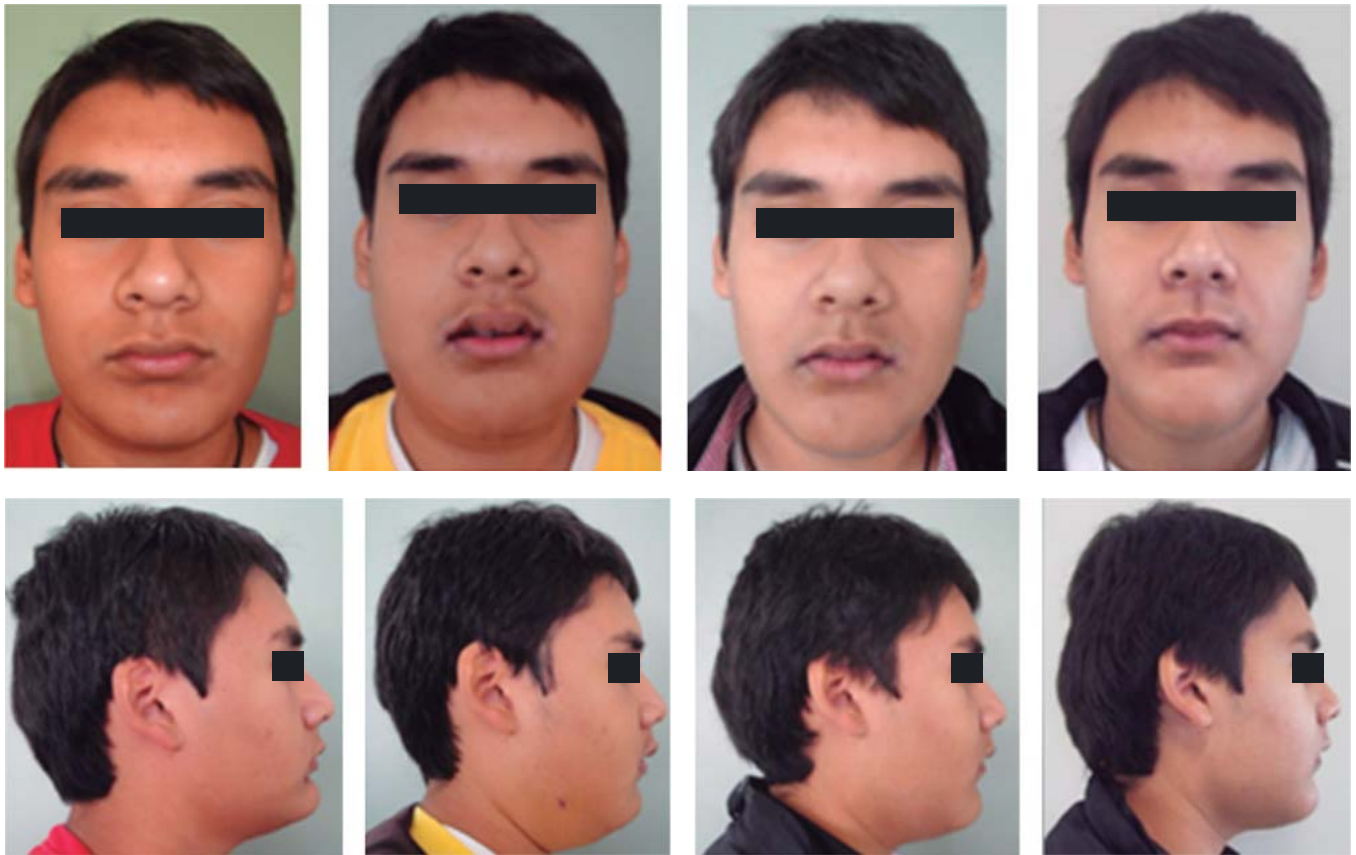

Figure 8. Evolution: 7, 15 and 30 days after surgery.

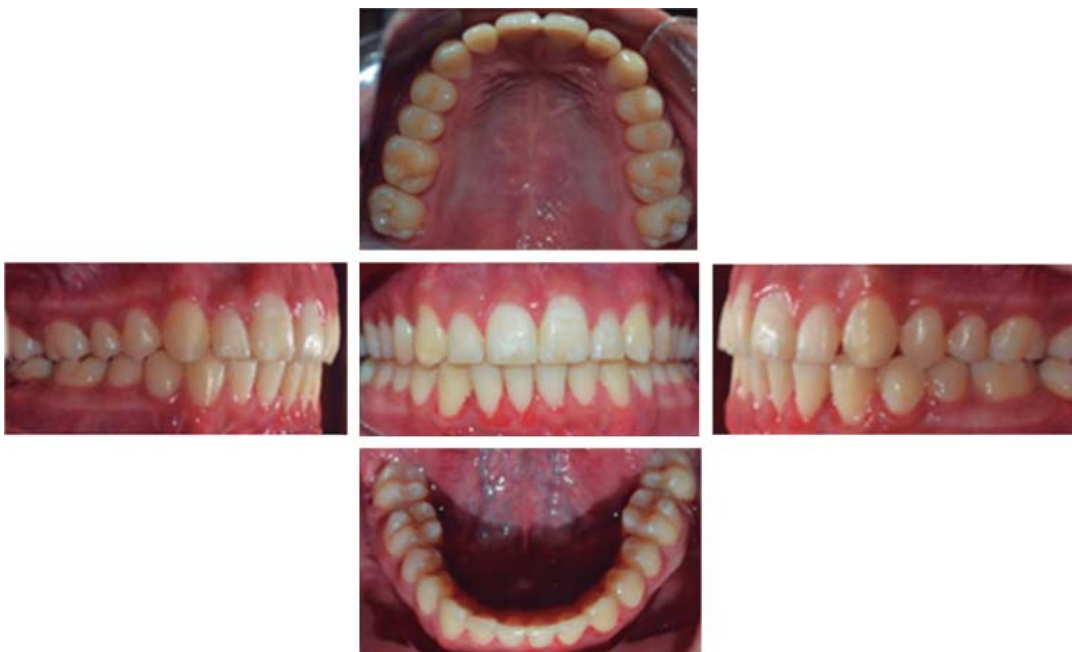

Figure 9.

Final photographs.

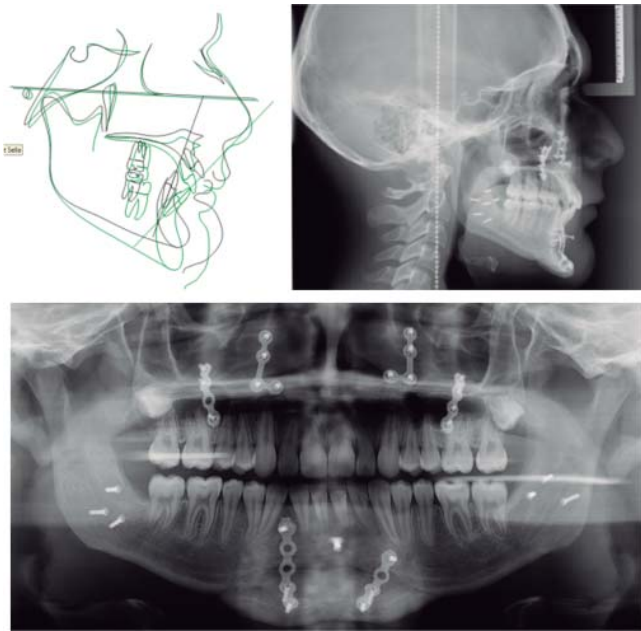


Figure 10. Final radiographs.

crowding was eliminated; molar and canine class I was achieved; an adequate overbite and overjet, maximal intercuspation and canine guidance were obtained (Figures 10 to 12 and Table I).

DISCUSSION

It is important to take into consideration aesthetics and facial and dental harmony since currently, facial esthetics is highly valued by society in general and we must consider the therapeutic options for treating class II malocclusions as well as their effect on the patient's profile.^{1,2}

Profile changes are subjective, because the point of view varies from person to person, depending on the sociocultural environment. Therefore, it is recommended to study facial and dental proportions to balance such aesthetics.¹⁴

To perform a proper interdisciplinary diagnosis, taking into consideration the patient's expectations and carefully assessing the treatment plan is important for achieving the set objectives and for being able to improve the patient's social setting.^{1,2,14}

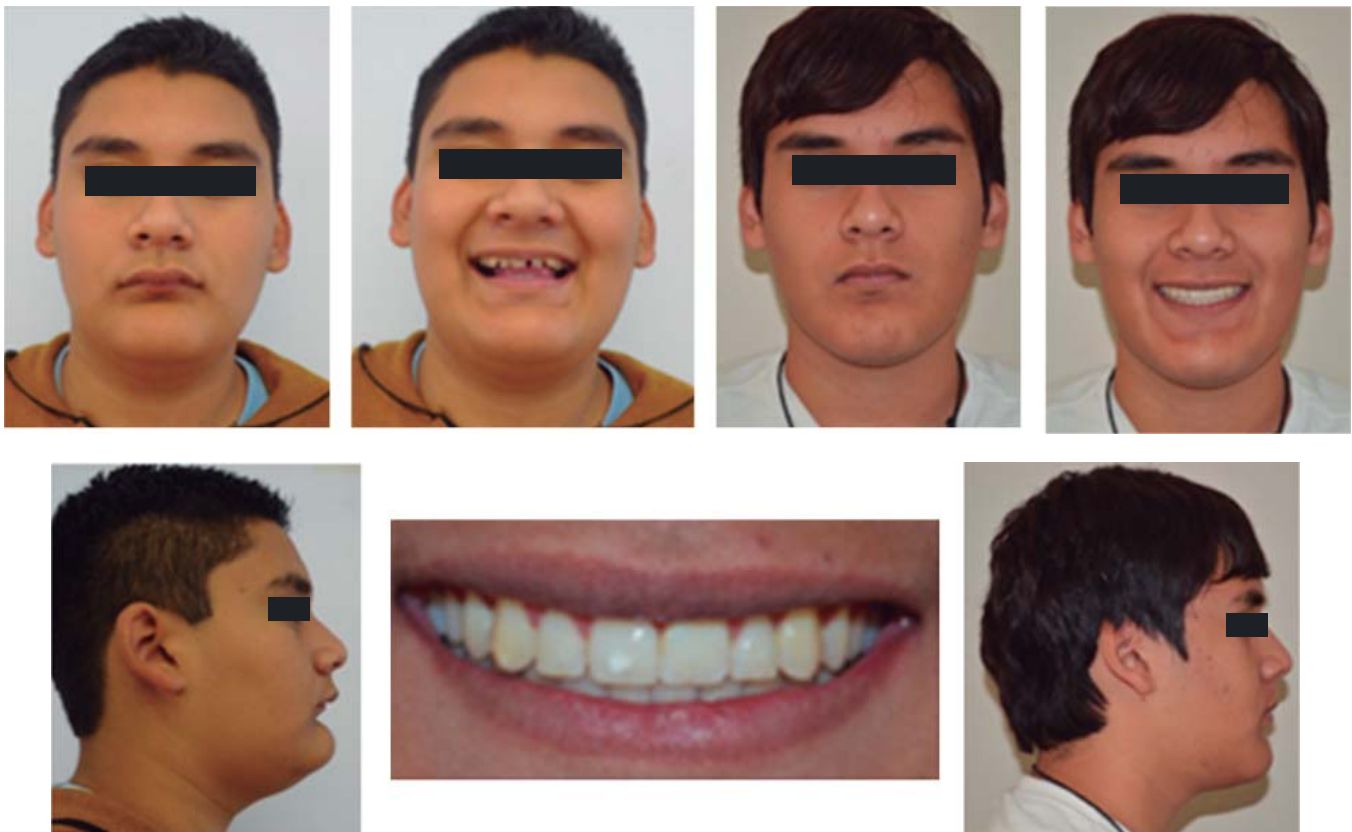

Figure 11. Initial and facial photographs.

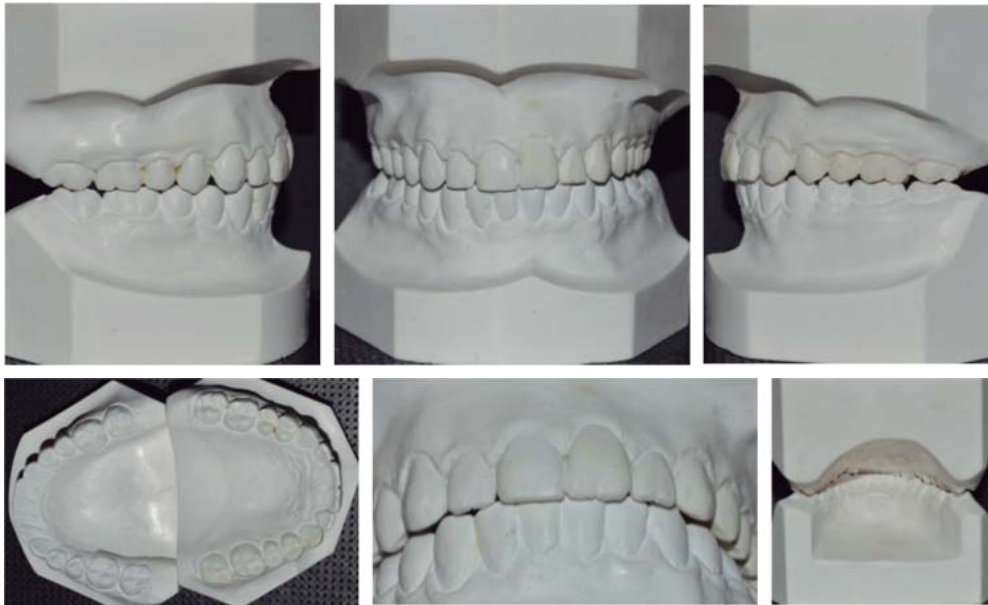

Figure 12.

Final models.

Table I. UNAM analysis.

Angle	Normal value	Patient	
Skeletal class		Start/End	
SNA (Steiner)	82° ± 3.5°	78	81
SNB (Steiner)	79° ± 4°	79	78
ANB (Steiner)	3° ± 2°	1	3
Facial angle (Downs)	88° ± 4°	91	87.5
Convexity (Downs)	5° ± 5°	-14	-5
Direction of growth			
Go-Gn -FH angle (Downs)	24° ± 5°	17.5	29.5
S-Ar-Go Angle sum (Bjork)	394° ± 7°	382	396
Goniac angle (Bjork)	119° ± 7°	114	127
Growth direction (Jarabak)	66%-6%	74	64.8
Incisor position			
1 S-N angle (Jarabak)	105° ± 7°	116	106
1 Go-Gn angle (Tweed)	97° ± 7°	88	102
Interincisal angle (Tweed)	125° ± 10°	113	117
Lip aesthetics			
Upper lip (Ricketts)	-3 ± 2 mm	-3	-5
Lower lip (Ricketts)	1 ± 3 mm	-10	-7

CONCLUSION

Interdisciplinary communication and the patient's perception are important to perform a good diagnosis and select the best treatment alternative for the patient's benefit, favoring function, aesthetics and providing greater self-confidence for the patient to interact in their social environment.

REFERENCES

1. Yin L, Jiang M, Chen W, Smales RJ, Wang Q, Tang L. Differences in facial profile and dental esthetic perceptions between young adults and orthodontists. *Am J Orthod Dentofacial Orthop.* 2014; 145 (6): 750-756.
2. Rivera SM, Hatch JP, Rugh JD. Psychological factor associated with orthodontic surgical treatment. *Semin Orthod.* 2000; 6: 259-269.
3. Minich CM, Araújo EA, Behrents RG, Buschang PH, Tanaka OM, Kim KB. Evaluation of skeletal and dental asymmetries in Angle Class II subdivision malocclusions with cone-beam computed tomography. *Am J Orthod Dentofacial Orthop.* 2013; 144 (1): 57-66.
4. Lima Filho RM, de Oliveira RAC. Long-term maxillary changes in patients with skeletal Class II malocclusion treated with slow and rapid palatal expansion. *Am J Orthod Dentofacial Orthop.* 2008; 134 (3): 383-388.
5. Baccetti T, Stahl F, McNamara JA Jr. Dentofacial growth changes in subjects with untreated Class II malocclusion from late puberty through young adulthood. *Am J Orthod Dentofacial Orthop.* 2009; 135 (2): 148-154.
6. Nishimura M, Sannohe M, Nagasaka H, Igarashi K, Sugawara J. Nonextraction treatment with temporary skeletal anchorage devices to correct a class II division 2 malocclusion with excessive gingival display. *Am J Orthod Dentofacial Orthop.* 2014; 145 (1): 85-94.
7. Vellini F. Ortodoncia: diagnóstico y planificación clínica. Sao Paulo: Editorial Las Artes Médicas; 2002. In: Escriván de Saturno L. Ortodoncia en dentición mixta. Caracas: Editorial Amolca; 2007.
8. Maj G, Lucchese FP. The mandible in class II, division 2. *Angle Orthod.* 1982; 52 (4): 288-292.
9. Proffit W. Ortodoncia contemporánea: teoría y práctica. 3ra ed. Madrid: Ed. Elsevier España SA; 2001.
10. Ishihara Y, Kuroda S, Sugawara Y, Kurosaka H, Takano-Yamamoto T, Yamashiro T. Long-term stability of implant-anchored orthodontics in an adult patient with a Class II Division

- 2 malocclusion and a unilateral molar scissors-bite. *Am J Orthod Dentofacial Orthop.* 2014; 145 (4): S100-113.
11. Moreno ULM, Howe SC, Kummet C, Vela KC, Dawson DV, Southard TE. Phenotypic diversity in white adults with moderate to severe Class II malocclusion. *Am J Orthod Dentofacial Orthop.* 2014; 145 (3): 305-316.
12. Ruf S, Pancherz H. Class II division 2 malocclusion: genetics or environment? A case report of monozygotic twins. *Angle Orthod.* 1999; 69 (4): 321-324.
13. Peck S, Peck L, Kataja M. Class II division 2 malocclusion: a heritable pattern of small teeth in well-developed jaws. *Angle Orthod.* 1998; 68 (1): 9-20.
14. González RMG, Lara MP. Corrección no quirúrgica del perfil de una maloclusión clase II. *Revista Mexicana de Ortodoncia.* 2014; 2(4): 278-262.
15. Alavi DG, BeGole EA, Schneider BJ. Facial and dental arch asymmetries in Class II subdivision malocclusion. *Am J Orthod Dentofacial Orthop.* 1988; 93 (1): 38-46.

Mailing address:

Sayra Nayelli Velázquez Serrano

E-mail: cdsayra08@hotmail.com